

1952

Surgical Repair of Umbilical and Inguinal Hernias in the Bovine

J. D. Wheat
University of California

Follow this and additional works at: http://lib.dr.iastate.edu/iowastate_veterinarian

 Part of the [Large or Food Animal and Equine Medicine Commons](#), and the [Veterinary Anatomy Commons](#)

Recommended Citation

Wheat, J. D. (1952) "Surgical Repair of Umbilical and Inguinal Hernias in the Bovine," *Iowa State University Veterinarian*: Vol. 14: Iss. 1, Article 3.

Available at: http://lib.dr.iastate.edu/iowastate_veterinarian/vol14/iss1/3

This Article is brought to you for free and open access by the College of Veterinary Medicine at Digital Repository @ Iowa State University. It has been accepted for inclusion in Iowa State University Veterinarian by an authorized administrator of Digital Repository @ Iowa State University. For more information, please contact hinefuku@iastate.edu.

Surgical Repair of Umbilical and Inguinal Hernias in the Bovine

*Dr. J. D. Wheat**

MANY different techniques have been described for hernia repair and all are aimed at securing the same result, a firm union of the opposing edges of the hernial ring.

In trying various described techniques, it has been felt there are some procedures which are undesirable and in the repair method to be described an attempt has been made to correct these faults.

Often times in calves the chief underlying factor in the etiology of umbilical hernia is infection of the umbilical cord. This may be in the form of an abscess or a diffusely enlarged umbilical cord. It is well to delay treatment until the calf is at least three months old as a small hernia may repair itself during this time.

Preparation for surgery should consist of fasting the animal for 24 hours or even 48 hours if the rumen is well filled. For calves, pentobarbital sodium given intravenously until the pedal reflex disappears, provides very satisfactory anesthesia. For older bovines, a sedative dose of chloral hydrate and 40 to 50 cc's of two percent procaine given epidurally provide satisfactory restraint.

A longitudinal elliptical incision is made through the skin including the umbilicus and hernial mass. This is then dissected directly down to the aponeurosis of the external oblique muscle which is stripped free of any areolar tissue and

fat towards the hernial ring until the elliptical area of skin and the hernial protrusions are attached only by the stalk-like neck of the hernial sac issuing through the umbilical ring.

After making sure that the hernial sac is free of all contents, it is amputated as close to the hernial ring as possible, as it

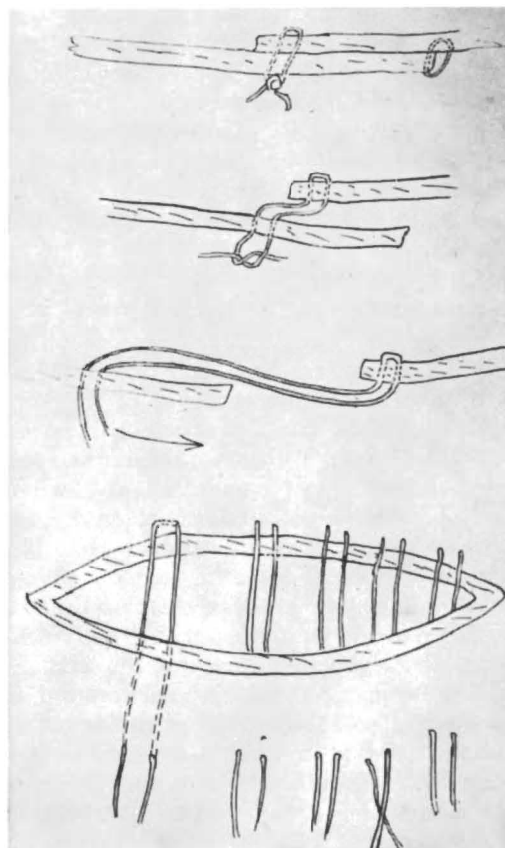


Fig. 1—Diagram of suturing technique in repair of umbilical hernia.

*Dr. Wheat received his D.V.M. at Cornell in 1945 and remained on the staff until 1948. He then spent two years teaching at Kansas State. In 1950 he became Assistant Professor of Veterinary Surgery at the University of California.

is of little use in the repair and only structures surrounding the ring are utilized for overlapping.

Closure of the peritoneum is not attempted. Suturing so as to produce an overlapping of the two halves of the abdominal wall is now carried out making sure that the under flap is stripped entirely free of fat and areolar tissue with bare fascia available to establish a broad area of contact.

Mattress sutures of No. 24 or 26 stainless steel wire are placed as follows: In the middle of the upper flap the suture is passed through the entire thickness of the abdominal wall from without inwards about two in. from the margin. The needle then takes a strong longitudinal bite through the lower flap near its margin and is carried out through the upper flap one-half in. to the side of the point of entry. Place as many of these sutures as are needed to close the hernial ring. After all the sutures are in place, they are drawn up so as to pull the lower flap well up in under the upper flap and the sutures tied. The free margin of the upper flap is now sutured fast to the opposing surface of the lower flap. The subcutaneous tissues are then united so as to obliterate the dead space and the skin closed.

After treatment consists of keeping the animal confined in a clean, dry stall.

As I stated previously, I feel that this method of repair has some advantages, one of which is the removal of the hernial sac. This peritoneal sac serves no useful purpose. It does not strengthen the hernial ring and if contaminated when forced back in the abdominal cavity, as it may well be in an animal that has had an umbilical infection it may set up peritonitis or an abscess. Also if the sac is left intact, it makes it virtually impossible to properly overlap the abdominal muscle as a fold of peritoneum is formed between the overlap making firm union of abdominal fascia impossible. Removal of the areolar tissue and fat from the flap to be drawn under is important as presence of this tissue will prevent a firm union between the two flaps. Stainless steel wire has been found to be a

most satisfactory suture material. It is strong and there is not the danger of its breaking as there is with catgut. It is non irritating and if the wound or suture becomes contaminated, it will not result in a foreign body fistula the way braided silk or cotton umbilical tape does.

The overlapping of the abdominal wall gives a relatively large area of reinforcement and in case of an extremely thin or weak abdominal wall, the maximum amount of support is given.

Inguinal Hernia

Although inguinal hernia is not common in the bull, it is a condition which requires diagnosis and surgical treatment if the bull is to be kept as a herd sire.

In early cases the presence of the intestine in the scrotum may be rather difficult to diagnose in very fat bulls due to the excess amount of fat that is present around the neck of the scrotum and it is not until the intestine is well down into the scrotum that a definite diagnosis can be made. Examination of the internal inguinal ring by rectal examination will reveal the loop of intestine passing through into the inguinal canal and scrotum. Here again excessive fatness is a hindrance. As the hernia becomes larger, the scrotum becomes pendulous causing the bull an inconvenience when moving about. The constant trauma to the scrotum may cause adhesions of the intestines in the hernial sac.

The technique for repairing an inguinal hernia in the bull is similar to that used in other species. With the bull lying on his side so that the affected side is up, an incision is made on the side of the scrotum its entire length. Care must be taken not to incise the hernial sac consisting of the parietal peritoneum and containing the testicle and intestine. The sac is then freed from its scrotal attachments and the intestines forced back into the abdominal cavity. If adhesions are present the hernial sac must be opened in order to break them down. The sac, containing only the spermatic cord and testicle, is then firmly ligated as close to the inguinal ring as possible and amputated distal to the ligature. The dorsal

half of the incision in the scrotum is then sutured and a gauze pack is placed in the inguinal canal making sure that it is firmly packed against the inguinal ring and secured below so that it will stay up in place. This pack is left in position for three to four days and then removed and the wound allowed to heal.

Dr. E. R. Frank in his text, *Veterinary Surgery Notes* describes the technique for closure of the internal inguinal ring by going through the flank and suturing the inguinal canal from within the abdominal cavity. On some cases, this method can be used satisfactorily.



Fig. 2—Inguinal hernia in a mature Hereford bull.

The bull shown in the photograph (Fig. 2) had a hernial ring five in. in diameter and according to the owner an attempt had been previously made to suture the inguinal ring through an incision made from the outside over the inguinal ring. The sutures did not hold and when the case was presented to me, the massive hernia was present. The intestines were extensively adhered in the hernial sac and the testicle was atrophied and also adhered. The hernia was reduced, the sac ligated close to the inguinal ring, and no attempt was made to close the ring. The inguinal canal was packed and left for four days. The bull made an uneventful recovery and is breeding satisfactorily today and at the end of one year following repair, the hernia shows no evidence of recurring.

Large fat bulls do not readily tolerate complete general anesthesia and being rolled up on their back. Epidural anesthesia plus a sedative dose of chloral hydrate provides satisfactory anesthesia and aids in the restraint of these animals.

References

1. Christopher, F. Textbook of Surgery, 4th Edition, W. B. Saunders Co., Philadelphia, 1945.
2. Frank, E. R., *Veterinary Surgery Notes*. 9144.

Cortisone

Cortisone, the rare compound so valuable in the treatment of arthritic conditions in man has up to this time been obtained from animal bile. The compound is so rare because, as reported, it requires the bile from approximately 40 animals to obtain one therapeutic human dose. Cortisone is a modified steroid. Research chemists of the U. S. Eastern Regional Research Laboratory, with plant search aid from the U. S. Bureau of Plant Industry, Soils, and Agricultural Engineering, have now isolated the unmodified steroid from various plants such as yuccas, yams, agaves and molinas. The U. S. public Health Service is studying the conversion of these plant steroids into cortisone. This, it is asserted, will be only a minor chemical change. If a plant can be commercially profitable to grow it, then cortisone may become sufficiently abundant to be available for veterinary use.

Splinting for large animals now seems practical according to a report from the Veterinary Clinic of the University of California. This splint was fashioned in the usual manner for quadrupeds, but the feature that is worthy of note is the use of electric conduit tubing which is composed of an aluminum alloy. The tubing in a 10-ft. length, $\frac{5}{8}$ in. in its outside diameter, with a wall-thickness of $\frac{1}{16}$ in. weighs only 3 lbs., and is suitable for splinting of all but the largest and heaviest of bovine or equine patients.

Chile produces 75 percent of the world's supply of iodine.