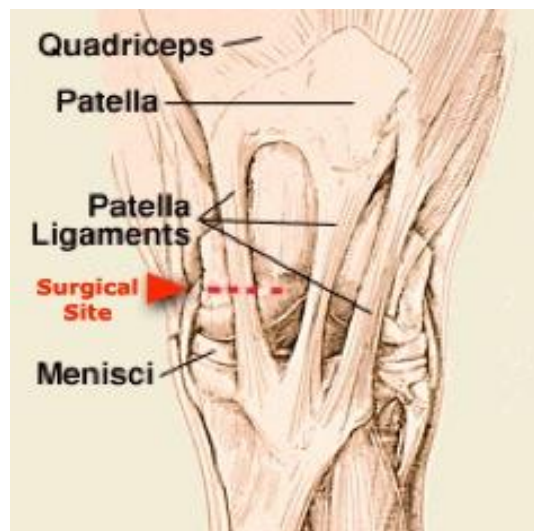


## Medial ligament desmotomy

This technique is done standing and the leg should be locked or bearing weight. The horse is sedated and skin at the area of the incision is anesthetized with local anesthetic, a fibular (peroneal nerve block can be done). A vertical incision several centimeters long is made over the ligament. A sharp, curved surgical instrument is passed under the ligament and the ligament is cut. The skin incision is sutured.

By cutting the medial patellar ligament completely, the patella no longer catches on the medial trochlear ridge of the femur, and so the stifle no longer locks.



This surgery should only be attempted if the horse is unresponsive to conservative treatments. Upper fixation of the patella can be rectified by pushing backward while synchronously pushing the patella medially and distally. Alternatively, pulling the limb forward with a rope around the pastern may unlock the patella.