

# How to Properly Position Thoroughbred Repository Radiographs

Katherine S. Garrett, DVM; and Jeffery T. Berk, VMD

Authors' addresses: Rood and Riddle Equine Hospital, PO Box 12070, Lexington, KY 40580 (Garrett); and Ocala Equine Hospital, 10855 NW Highway 27, Ocala, FL 34482 (Berk); e-mail: kgarrett@roodandriddle.com (Garrett). © 2006 AAEP.

## 1. Introduction

It is suggested by many major Thoroughbred sales companies that a standard set of radiographs accompany every weanling, yearling, and racing prospect offered for sale. These radiographs are submitted to the sales company and are available for viewing in a repository by potential buyers and/or their veterinarians. One of the goals of the repository system is to reduce the number of additional radiographs taken during the sale itself. Although a horse may have radiographs in the repository, re-takes are often requested by the potential purchaser's veterinarian to confirm a radiographic finding. Currently, many of these re-takes are caused by improperly positioned or poorly exposed repository radiographs. While some re-takes will always occur, the number could be significantly reduced if the radiographs in the repository were all of high quality. This paper will describe how to properly position each required view.

## 2. Materials and Methods

Each radiograph should be labeled clearly with the horse's hip number, the limb being radiographed, the date the films were taken, and the name of the veterinarian or practice who produced

the radiographs.<sup>1</sup> The label should be placed on the dorsal aspect of the limb for lateromedial views and on the lateral aspect of the limb for all other views.<sup>1</sup> The sales company determines the required time frame for the radiographs and publishes that information in the sales catalog.<sup>2</sup> Most commonly, the repository films must be taken within 2–3 weeks of the date that the horse will be offered for sale.

For all views, the horse should be standing squarely with all four limbs perpendicular to the ground. Poor limb position contributes significantly to poor quality radiographs. Attempting to adjust the angulation or elevation of the radiographic beam to compensate for incorrectly positioned limbs results in inconsistent radiographs. To reduce motion, the radiographic cassette should rest against the horse's limb whenever possible. The radiographic beam needs to be perpendicular to the cassette to reduce magnification of all or part of the joint; therefore, it is important to adjust not only the beam position, but the cassette position as well. Sedation may be necessary to obtain diagnostic radiographs and for safety reasons. The horse's limbs must be completely clean and dry to avoid artifacts on the radiographs.<sup>3</sup>

---

## NOTES

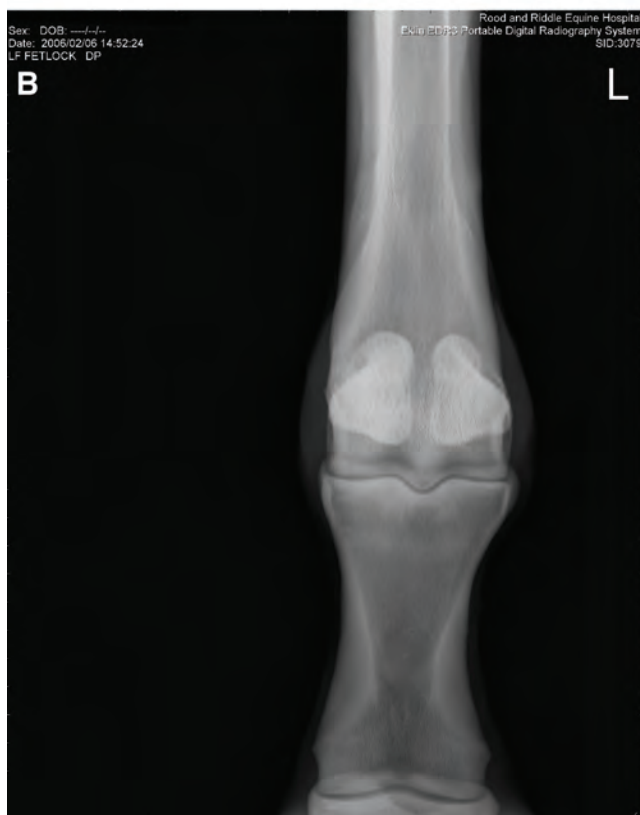
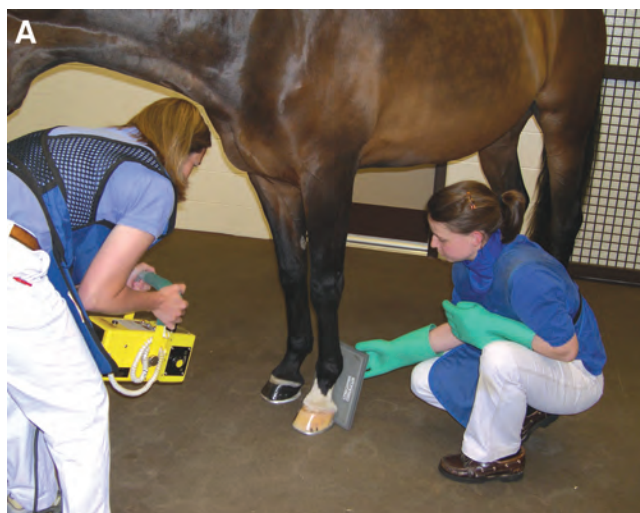
Fig. 1. (A) Positioning for a dorsal 15° proximal-palmar distal view of the fetlock. (B) Dorsal 15° proximal-palmar view of the fetlock.

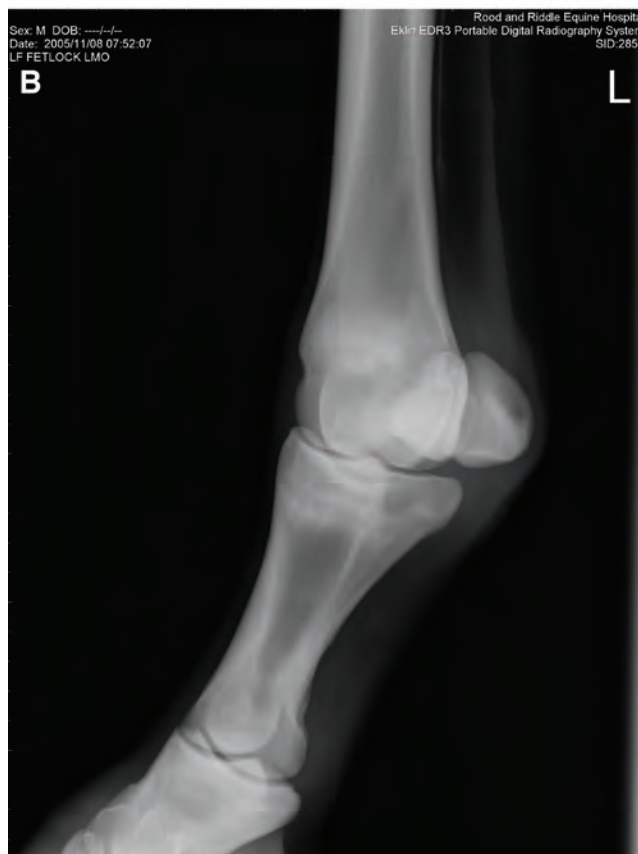
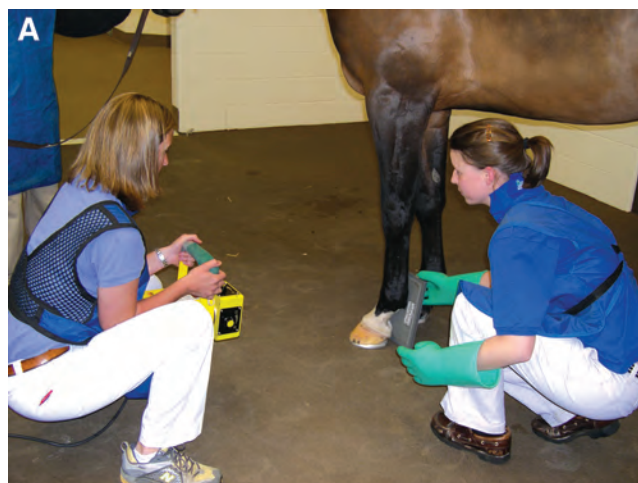
Fig. 2. (A) Positioning for a dorsal 10° proximal 30° lateral-palmar distal medial oblique view of the fetlock. (B) Dorsal 10° proximal 30° lateral-palmar distal medial oblique view of the fetlock.

The radiographer, the cassette holder, the horse handler, and anyone else in the area should wear protective lead aprons. Lead thyroid protectors are recommended, and the cassette holder should wear lead gloves. Radiation monitoring badges are necessary for anyone routinely exposed to radiation, and the exposure levels should be monitored closely. No one less than 18 years of age should be in the vicinity of the radiographic beam.<sup>3</sup>

A standard repository set includes 32 films for yearlings and weanlings and 34 films for horses of racing age. This includes four views of each fetlock, three views of each carpus (four views of each carpus for horses of racing age), three views of each tarsus, and two views of each stifle.<sup>2</sup> Each view will be considered individually below. The individual views listed in the subheadings are the views spec-

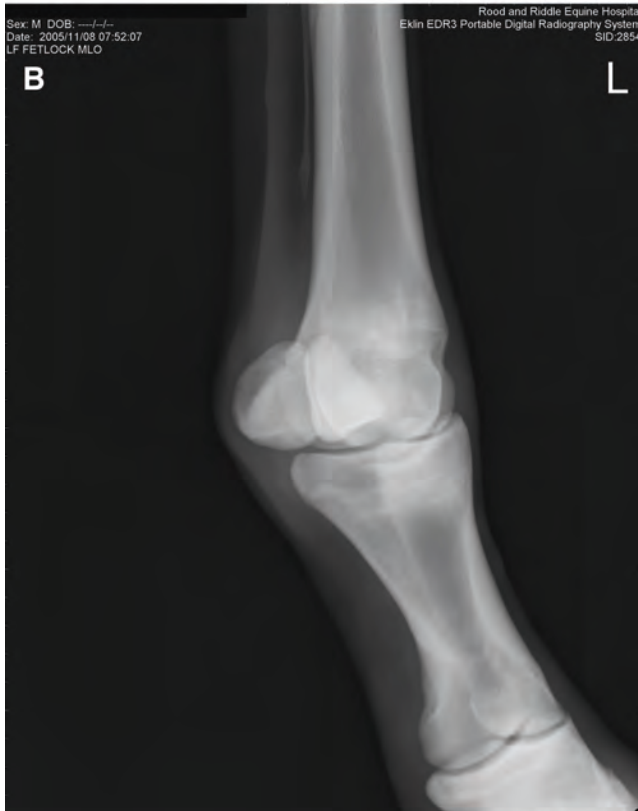
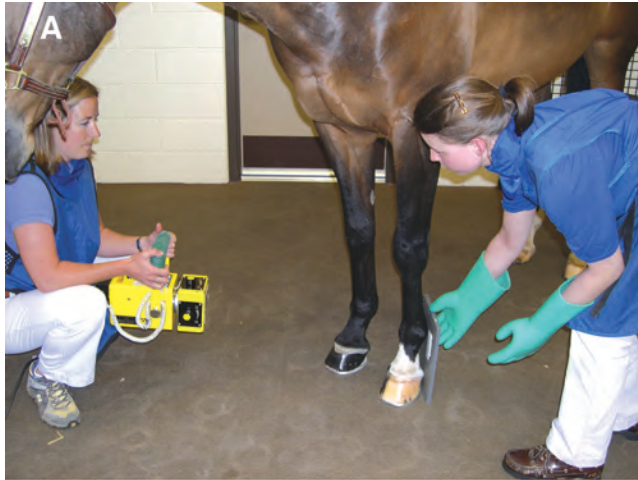
Fig. 3. (A) Positioning for a dorsal 10° proximal 30° medial-palmar distal lateral oblique view of the fetlock. (B) Dorsal 10° proximal 30° medial-palmar distal lateral oblique view of the fetlock.

ified by the Keeneland Association, one of the major Thoroughbred sales companies.<sup>2</sup>

**Fetlock**

When radiographing the fetlock, it is important to make sure the horse is not standing in a stall or other area with bedding. This allows for the cassette to be placed in a relatively more distal position that will permit evaluation of the pastern region as well.

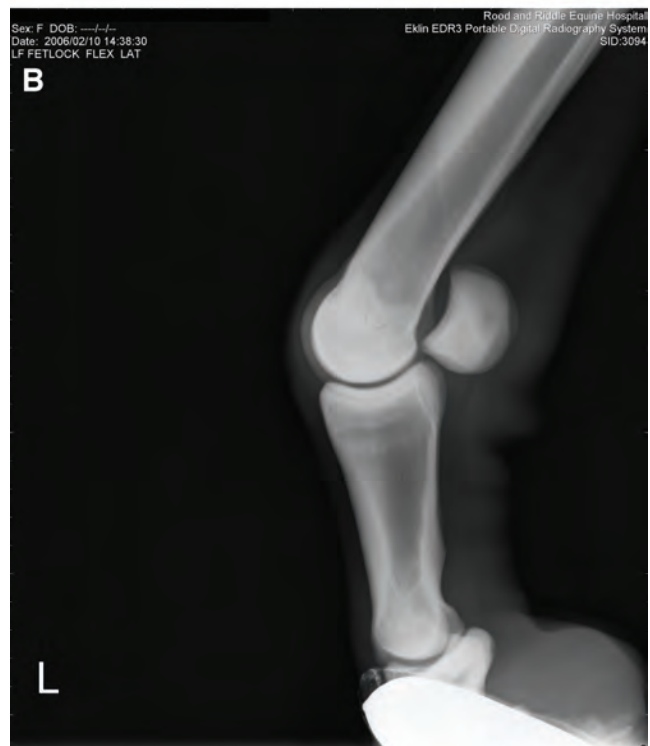
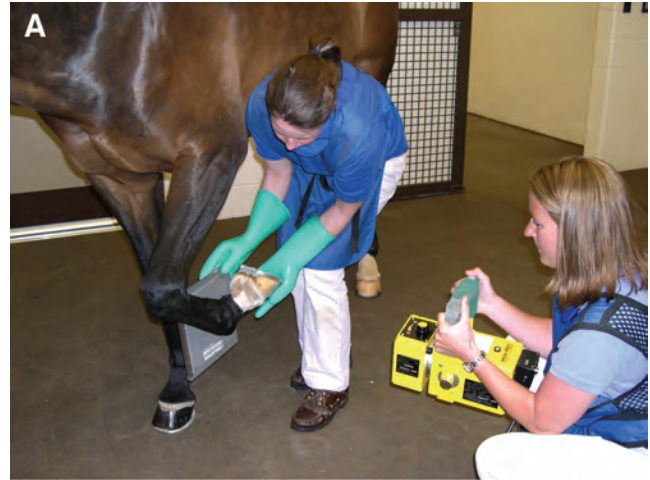

Fig. 4. (A) Positioning for a flexed lateral-medial view of the fetlock. (B) Flexed lateral-medial view of the fetlock.

**Dorsal 15° Proximal-Palmar Distal (Plantar) View**

The radiographic beam is positioned in line with the sagittal ridge of the fetlock (Fig. 1). A common mistake is to line up with the sagittal plane of the hoof or the pastern. The beam should be elevated 15–20° from horizontal in the fore limbs and 20–25° in the hind limbs. The elevation is necessary to separate the distal aspect of the proximal sesamoid bones from the joint surface, permitting evaluation of the perimeter of the joint for osteophytes and chip fractures and visualization of the metacarpal (tarsal) condyles.<sup>4</sup>

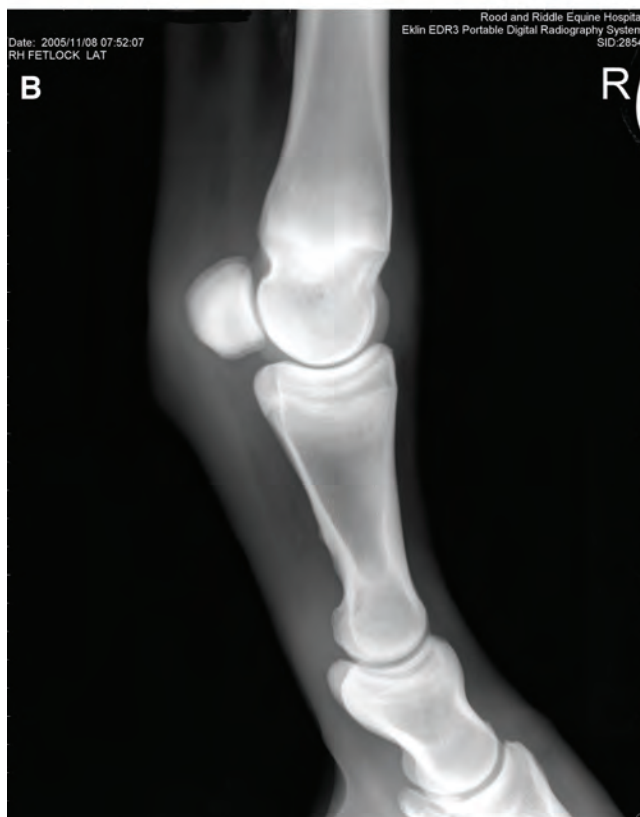

Fig. 5. (A) Positioning for a standing lateral-medial view of the fetlock. (B) Standing lateral-medial view of the fetlock.

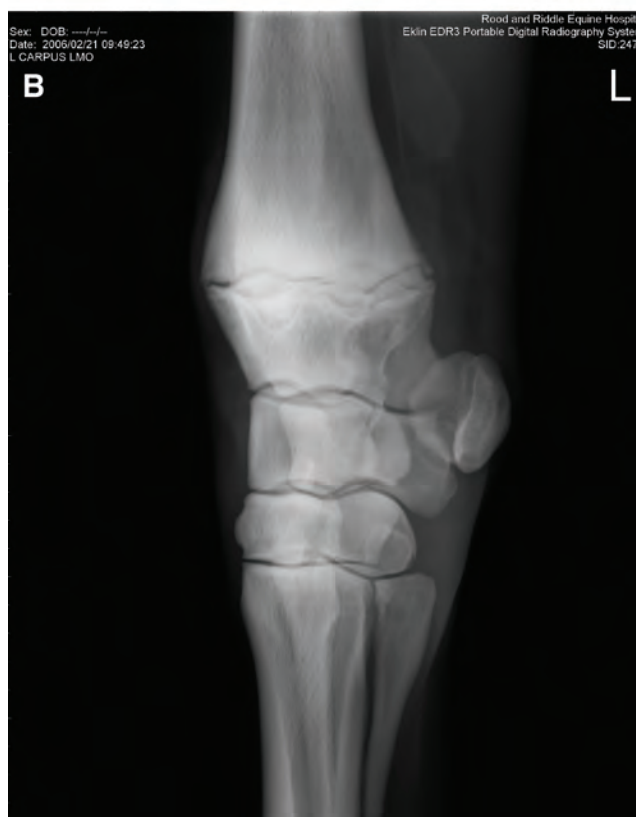
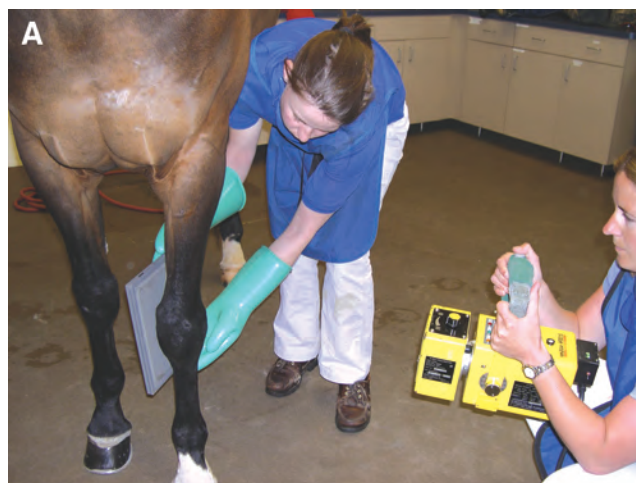
Fig. 6. (A) Positioning for a dorsal 55° lateral-palmar medial oblique view of the carpus. (B) Dorsal 55° lateral-palmar medial oblique view of the carpus.

*Dorsal 10° Proximal 30° Lateral-Palmar (Plantar) Distal Medial Oblique View and Dorsal 10° Proximal 30° Medial-Palmar (Plantar) Distal Lateral Oblique View*

This view is taken at 30–40° lateral (or medial) from the sagittal plane and is elevated slightly to separate the proximal sesamoid bones from the joint surface (Figs. 2 and 3). The radiographic beam should be elevated 5–10° in the fore limb and 10–15° in the hind limb. The proximal ses-

amoid bones should overlap one another slightly, and the palmar/plantar aspect of the joint should have enough space to locate fragments from the distal aspect of the proximal sesamoid bones or the proximal aspect of the first phalanx (P1). This allows visualization of condyle lucencies without overlap of the proximal sesamoid bones. The dorsomedial (or dorsolateral) extensor process of proximal P1 should be curved smoothly to assess for dorsal P1 chips. If the elevation is too

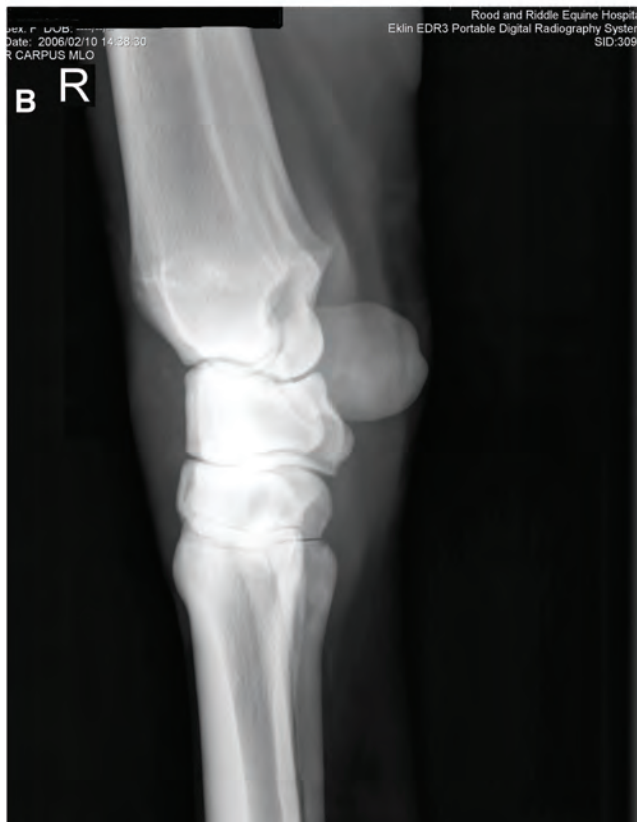
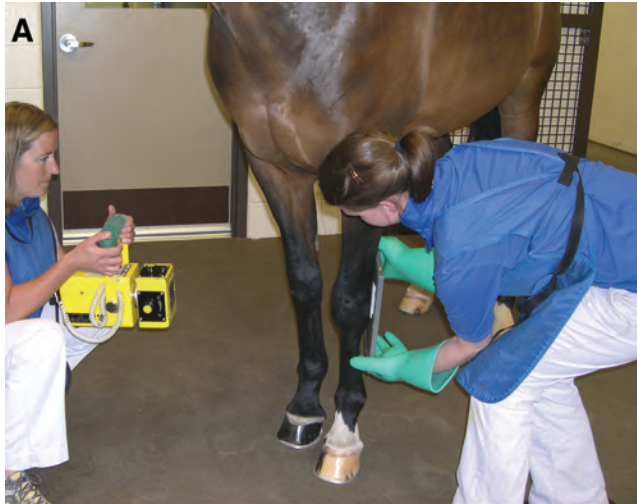
Fig. 7. (A) Positioning for a dorsal 65° medial-palmar lateral oblique view of the carpus. (B) Dorsal 65° medial-palmar lateral oblique view of the carpus.

step, the dorsal aspect of P1 will be obscured, potentially hiding a chip.<sup>4</sup> If the elevation is not steep enough, the palmar/plantar aspect of the joint may be obstructed from view because of overlap from the proximal sesamoid bones.<sup>4</sup> The more distally the sesamoids are positioned relative to the rest of the fetlock, the more elevation is required. The opposite is true for more proxi-

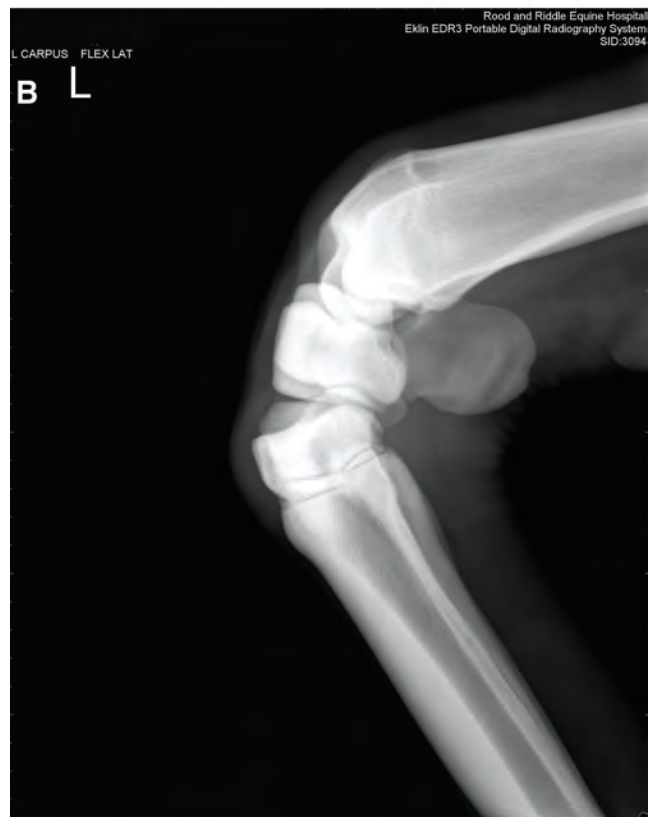
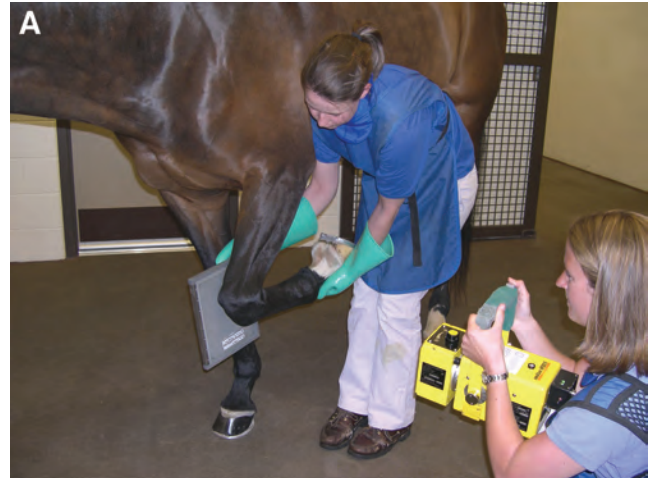
Fig. 8. (A) Positioning for a flexed lateral-medial view of the carpus. (B) Flexed lateral-medial view of the carpus.

mally positioned sesamoids as seen in upright limb conformation.

#### *Flexed Lateral-Medial View*

This is required in the fore limb only (Fig. 4). The cassette holder holds the limb under the horse's body in a natural degree of flexion, allowing assessment of both the proximal and distal portions of the sagittal ridge for osteochondrosis (OCD) lesions. The radiographic beam is perpendicular to the sagittal ridge and

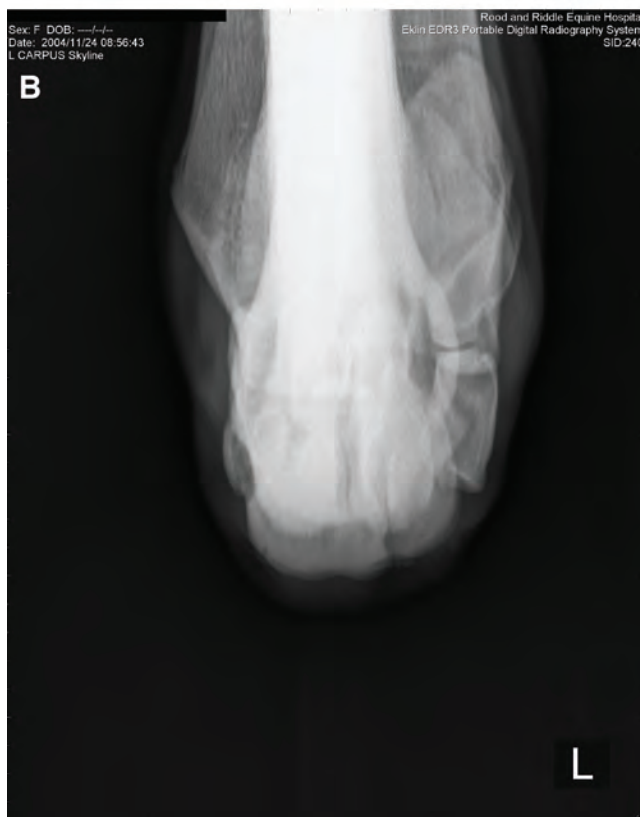

Fig. 9. (A) Positioning for a dorsal 30° proximal-dorsal distal view of the carpus. (B) Dorsal 30° proximal-dorsal distal view of the carpus.

directly lateral to the fetlock. It is important that the proximal and distal sagittal ridge is visible, and the sesamoids are superimposed.<sup>4</sup>

#### *Standing Lateral-Medial View*

This is required in the hind limb only (Fig. 5). The radiographic beam should be perpendicular to the fetlock joint itself. Lining up perpendicular to

the heel bulbs will result in a beam position dorsal to the lateral plane. Using the suspensory ligament as a guide can be helpful in finding the correct angle. The sesamoids should be superimposed, and the sagittal ridge should be well defined to allow visualization of possible OCD lesions.<sup>4</sup>

#### Carpus

##### *Dorsal 55° Lateral-Palmar Medial Oblique View*

This angle highlights the dorsomedial aspects of the radial carpal bone, third carpal bone, and distal radius, all of which are common sites for chip fractures and osteophyte formation (Fig. 6). Each joint space should be clearly visible without superimposition of carpal bones of adjacent rows. The accessory carpal bone can also be evaluated for fractures.<sup>5</sup>

##### *Dorsal 65° Medial-Palmar Lateral Oblique View*

This view is used to assess the dorsolateral aspects of the intermediate carpal bone, distal radius, and third carpal bone, which are also sites of osteophyte and chip fracture formation (Fig. 7). Slab fractures of the third carpal bone may be visible as well. As with the opposite oblique view, the joint spaces should be visible.<sup>5</sup>

##### *Flexed Lateral-Medial View*

The carpus should be flexed to approximately one half of its maximal flexion and pushed dorsally to separate the intermediate and radial carpal bones (Fig. 8). This allows confirmation of chip fractures and osteophytes.<sup>5</sup>

##### *Dorsal 30° Proximal-Dorsal Distal (Third Carpal Bone Skyline) View*

This view is required only for horses of racing age (Fig. 9). It allows evaluation of the dorsal aspect of the weight-bearing surface of the third carpal bone for slab fractures and sclerosis.<sup>5</sup> The cassette holder flexes the carpus to its maximal point with her hand at the fetlock joint and the cannon bone directly below the radius and pushes the carpus dorsally. The radiographic beam is positioned in front of the horse in line with the dorsal face of the third carpal bone and angled distally ~30°, but this angle can vary depending on how the limb is held.

#### Tarsus

##### *Dorsal 10° Lateral-Plantar Medial View*

The slightly oblique angle of this view allows evaluation of the medial malleolus of the tibia without superimposition on the talus, as the medial malleolus is a common site of OCD lesions (Fig. 10).<sup>6</sup> The distal tarsal joint spaces may be evaluated as well. To properly visualize the distal tarsal joints, the radiographic beam should be centered on and through these joint spaces.<sup>6</sup>

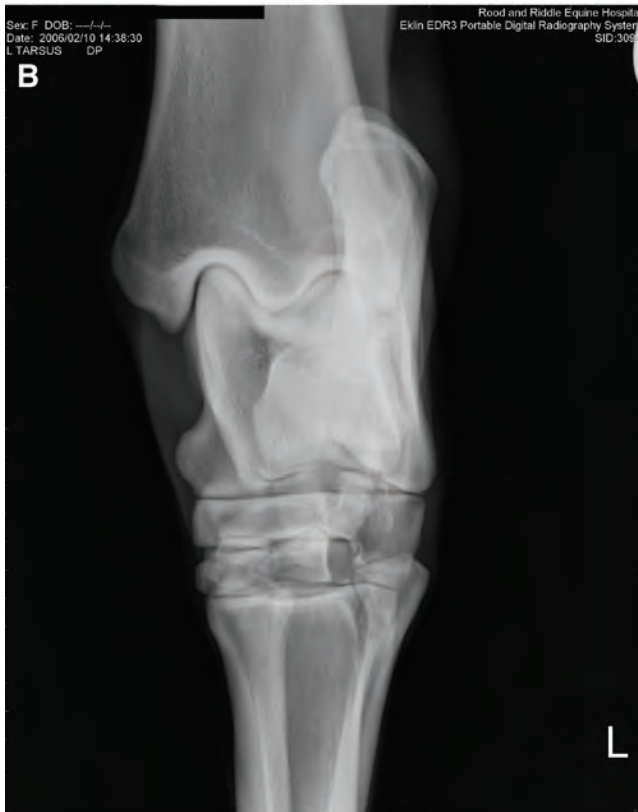
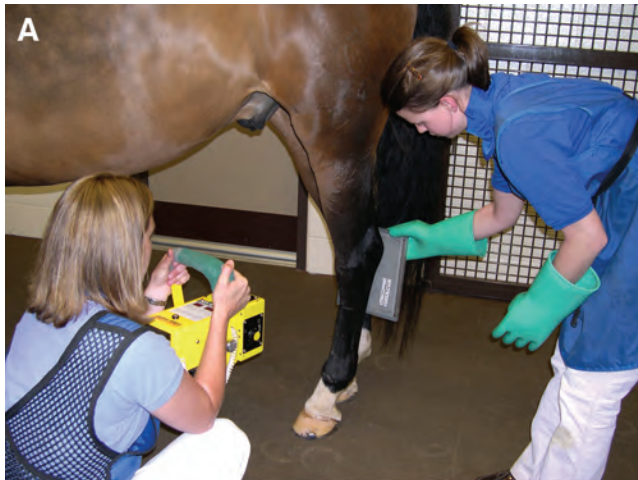
Fig. 10. (A) Positioning for a dorsal 10° lateral-plantar medial view of the tarsus. (B) Dorsal 10° lateral-plantar medial view of the tarsus.

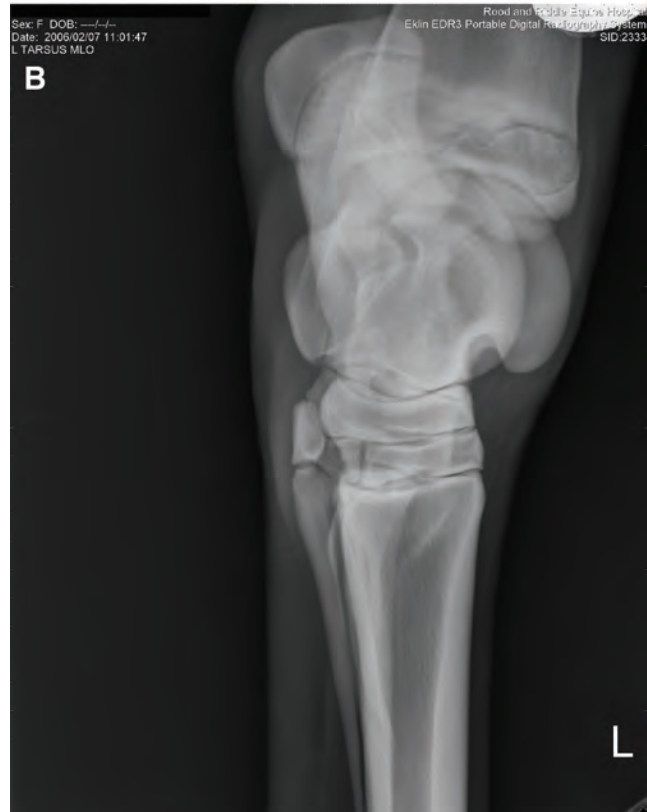

Fig. 11. (A) Positioning for a dorsal 25° medial-plantar lateral view of the tarsus. (B) Dorsal 25° medial-plantar lateral view of the tarsus.

*Dorsal 25° Medial-Plantar Lateral View*

The distal intermediate ridge of the tibia and the distal aspect of the lateral trochlear ridge, both potential sites of OCD lesions, should be clearly visible (Fig. 11).<sup>6</sup> The radiographic beam should be dorsal enough so that the distal lateral trochlear ridge is not obscured behind the medial trochlear ridge. The distal tarsal joint spaces should be well delineated to allow inspection for osteophyte formation

with the beam directed as described for the dorsal 10° lateral-plantaromedial view.

*Lateral-Medial View*

The radiographic beam should be perpendicular to the trochlear ridges of the talus, not to the horse's body for a true lateromedial view (Fig. 12). The trochlear ridges of the talus should be superimposed and the distal tarsal joints should not be overlapped.

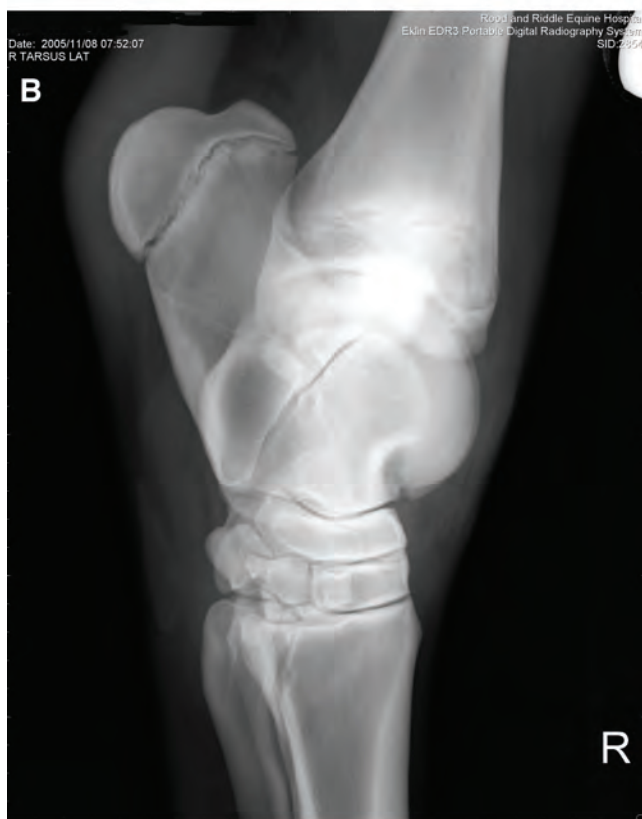
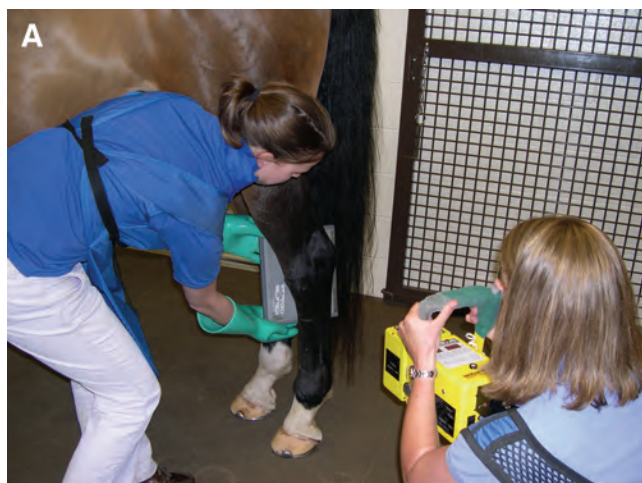
Fig. 12. (A) Positioning for a lateral-medial view of the tarsus. (B) Lateral-medial view of the tarsus.

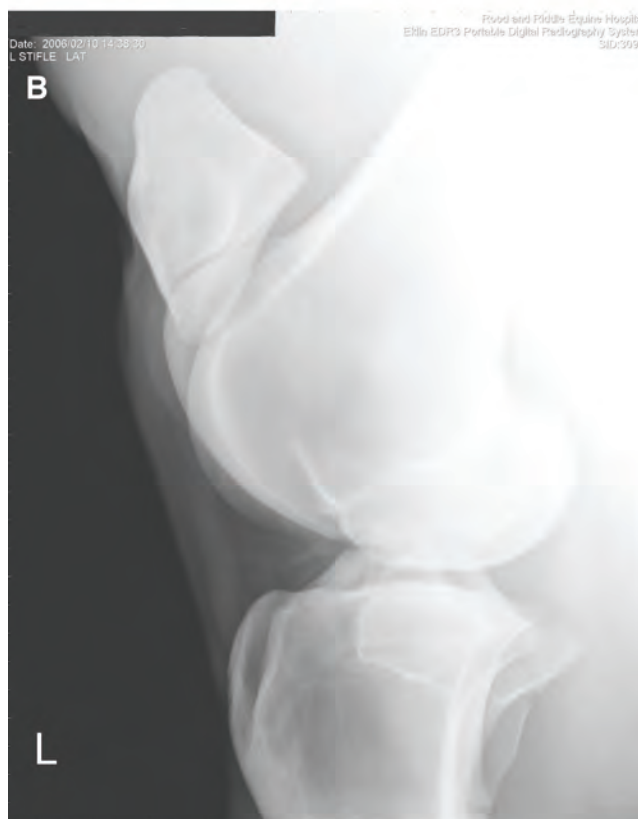

Fig. 13. (A) Positioning for a lateral-medial view of the stifle. (B) Lateral-medial view of the stifle.

This allows evaluation of the distal tarsal joint spaces, the distal intermediate tibial ridge, and the distal trochlear ridges.<sup>6</sup>

#### Stifle

##### *Lateral-Medial View*

The radiographic beam is positioned lateral to the stifle and parallel with the ground (Fig. 13). A common mistake is to position the beam lateral to the body of the horse instead of to the stifle. This error will

result in an overly cranial position of the beam, and the lateral trochlear ridge will be obscured. In a true lateral view, the femoral condyles will be superimposed. The cassette should be positioned proximally enough to completely show both trochlear ridges and the patella, all of which are sites of OCD lesions.<sup>7</sup>

##### *Caudal 10° Proximal 20° Lateral-Cranial Distal Medial Oblique View*

This view is angled slightly distally (10–15°) to view the medial femorotibial joint space (Fig. 14). The



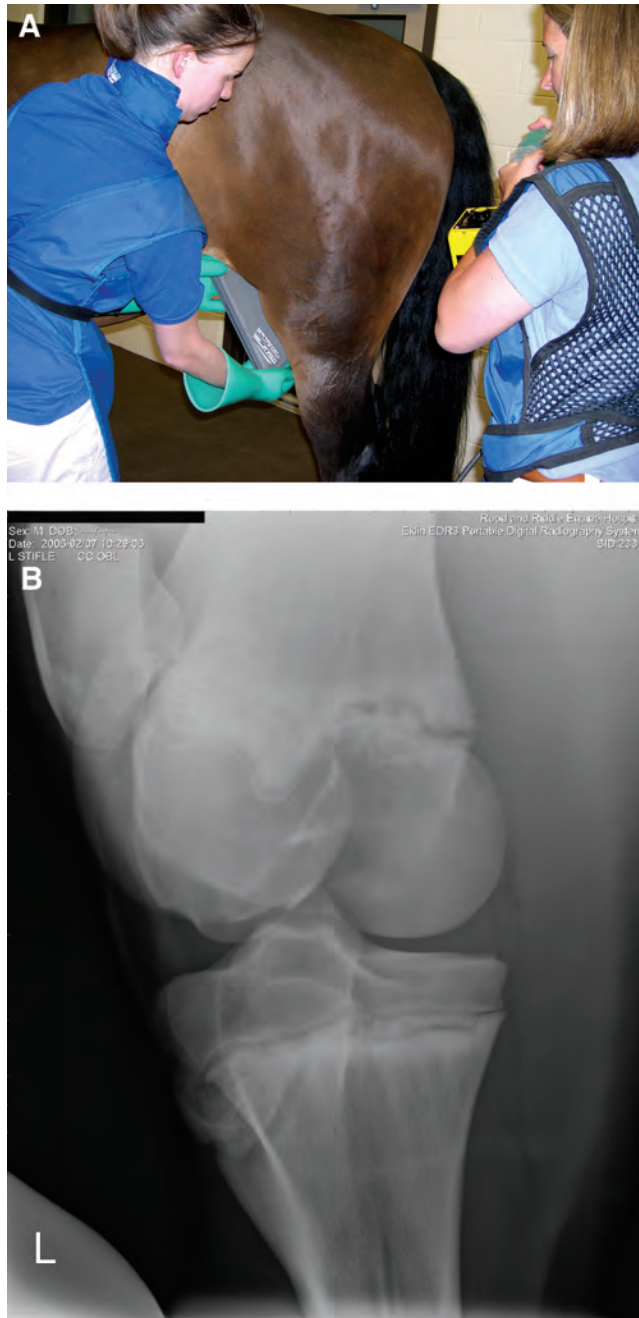

Fig. 14. (A) Positioning for a caudal 10° proximal 20° lateral-cranial distal medial oblique view of the stifle. (B) Caudal 10° proximal 20° lateral-cranial distal medial oblique view of the stifle.

radiograph must allow for visualization of both the medial femoral condyle and the abaxial aspect of the lateral trochlear ridge.<sup>7</sup> To achieve adequate visualization of the abaxial aspect of the lateral trochlear ridge, it may be necessary to be 30–40° lateral to the caudal plane.

### 3. Results

These positioning guidelines will aid in creating radiographs that highlight the most common lesion

locations. It is important to note that the angles specified here are guidelines, and individual variations in conformation may necessitate slightly different angulation or elevation to allow optimal visualization of lesion sites.

The most vital aspect of producing high-quality radiographs is critical assessment of the resultant films. All sites of potential lesions must be adequately visualized. If the films are poorly positioned, incorrectly exposed, or have motion or artifacts, they must be retaken until acceptable films are obtained.

### 4. Discussion

Purchasing horses at a public auction has inherent risks. Sales companies attempt to decrease these risks to buyers by defining specific conditions of sale and by providing a means by which information about the horses offered for sale can be disseminated. Adequate information must be available to the potential buyers without creating an undue burden on the consignors and sellers. The existence of a radiograph repository is an excellent compromise; however, it is only as good as the information it contains. If there are poor-quality radiographs in the repository, it leads to additional expense for the potential buyers to re-take radiographs as well as inconvenience for the consignors/sellers. In addition to the expense, there is great risk for buyers in purchasing an individual that cannot be properly evaluated radiographically on a pre-sale basis because of inadequate repository films. This is especially true in cases where re-take radiographs cannot be obtained because of time constraints or the inability to tranquilize horses being shown.

Increasing the overall quality of the films in sales repositories has multiple benefits. The consignors and sellers do not have to make the horse available for multiple re-examinations. Buyers' veterinarians are able to make judgments about potential lesions based on the films in the repository rather than having to require individual re-takes to feel confident in making a radiographic diagnosis. Re-takes themselves can become costly for the buyers. It is important to note also that the quality of the repository information is also a direct reflection on the veterinarian who produced the radiographs. There is some degree of inconvenience involved in re-taking radiographs; however, this should be accepted as a responsibility of representing each horse as accurately as possible.

### References

1. Hance SR, Morehead JP. Radiographic Thoroughbred yearlings for the repository, in *Proceedings*. 46th Annu Conv Am Assoc Equine Pract 2000;359–361.
2. Keeneland Association. Terms, conditions, and procedures binding upon consignors and buyers. Keeneland Repository 2006 April two-year-olds in training sale guidelines (letter to veterinarians). Feb 28, 2006.
3. Butler JA, Colles CM, Dyson SJ, et al. *Clinical Radiology of the Horse*, 2nd ed. Oxford, UK: Blackwell Science, 2000;3–6.

4. Butler JA, Colles CM, Dyson SJ, et al. *Clinical Radiology of the Horse*, 2nd ed. Oxford, UK: Blackwell Science, 2000; 109–126.
5. Butler JA, Colles CM, Dyson SJ, et al. *Clinical Radiology of the Horse*, 2nd ed. Oxford, UK: Blackwell Science, 2000; 173–203.
6. Butler JA, Colles CM, Dyson SJ, et al. *Clinical Radiology of the Horse*, 2nd ed. Oxford, UK: Blackwell Science, 2000; 249–284.
7. Butler JA, Colles CM, Dyson SJ, et al. *Clinical Radiology of the Horse*, 2nd ed. Oxford, UK: Blackwell Science, 2000; 288–319.