

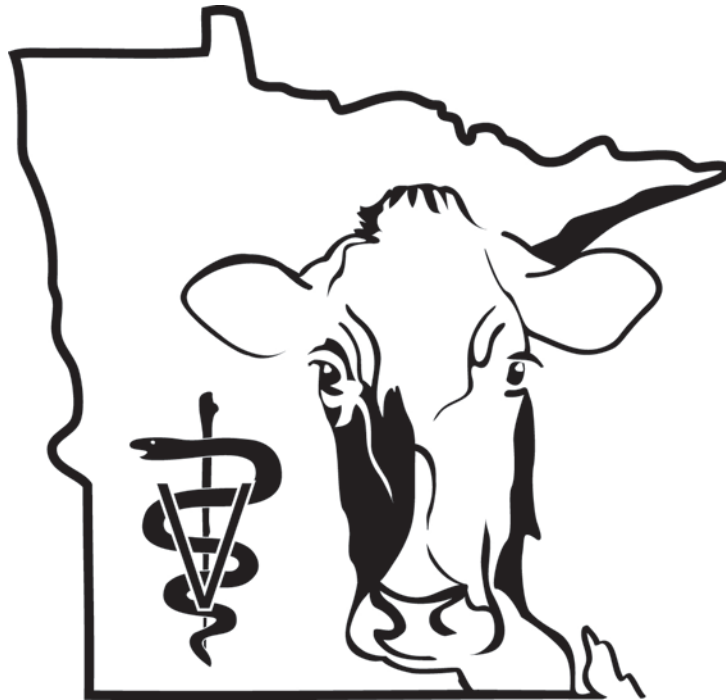THIS ARTICLE IS SPONSORED BY THE
MINNESOTA DAIRY HEALTH CONFERENCE.



UNIVERSITY OF MINNESOTA

College of Veterinary Medicine

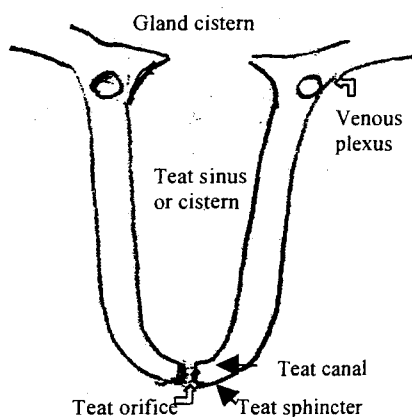
VETERINARY CONTINUING EDUCATION



ST. PAUL, MINNESOTA
UNITED STATES OF MINNESOTA

Implants or real? Or Surgical options for teat and udder surgery

Erin Malone
College of Veterinary Medicine
University of Minnesota



The majority of cases presented to the UMN Veterinary Teaching Hospital involve poor or non-existent milk flow from one quarter or abnormal teat structure. We will discuss the pathophysiology involved in these cases and present some surgical options. However, many of these are frustrating and poorly responsive to the available therapeutic options.

No milk flow

Heifers entering their first lactation are the group most commonly affected with this disorder. Lack of milk flow is usually related to obstruction at the level of the teat or at the junction between the teat and the gland. In many cases, both the gland and teat are okay but a membranous shelf is present at the base of the teat, preventing milk from entering the teat cistern. In other cases the lumen may abnormally developed (or just not present) or the teat orifice may be absent. In other animals (heifers included), scarring may have developed previously which is now obstructing milk flow. Rarely is the gland itself primarily affected.

Diagnostic evaluation includes palpation and comparison to other teats, attempted passage of a blunt teat cannula, and ultrasound. Additional options include xeroradiography or contrast radiography, with contrast material injected into the udder. Careful palpation may reveal scarring from previous trauma or mastitis, and occasionally one can determine whether milk is actually entering the teat canal. The teat cannula must be inserted carefully to prevent iatrogenic damage. It can be used as a deep probe to evaluate the integrity and smoothness of the mucosal lining as well as to determine the depth of the lesion and/or the length of the open canal. In many cases of a proximal membranous lesion, the teat cannula can be inserted the length of the teat but milk flow is still not obtained. Ultrasound is used to evaluate the extent of scarring and/or milk flow into the canal. It is also used to evaluate the gland: if milk does not enter collecting ducts properly or if the collecting ducts are themselves abnormal, doing surgery on the teat may not be rewarding. We compare the gland to its opposite quarter (e.g. rear gland to rear gland) since there are differences between front and rear quarters. Most cases will have a mild-moderate decrease in the amount and size of the collecting ducts; we generally pursue treatment unless the

discrepancy is marked. After 5-7 days, the quarter will stop milk production and milk flow will be much diminished for that lactation even if the obstruction is relieved. However, the quarter should resume normal production the next lactation and surgery can be done at that time if desired. In most instances it is not prudent to do surgery at this stage as most treatments will not last beyond one lactation.

Membranous shelf between teat and gland : These are among the most common lesions seen. The teat palpates normally and appears normal on ultrasound except for the absence of a teat canal. No milk is observed entering the teat. A teat cannula can be passed the length of the teat. The goal of surgery is to open the membrane and allow milk to enter the teat canal. This can be done through the teat orifice or via theotomy. A teat bistoury is used to make 4-5 slices in the membrane or Kelly hemostatic forceps are repeatedly pushed through the membrane and then opened to widen the new opening. Other options include using a Hudson spiral teat instrument (instrument twisted in and then yanked out) or Alligator forceps used to grab and tear the membrane. Care must be taken if working through the teat orifice as it is very easy to overstretch or damage the teat sphincter. It is also important to avoid cutting into the venous plexus surrounding the base of the teat. In many instances, a silicone teat prosthesis is inserted to keep the membrane open. If it is not used, it is important to maintain milk flow and prevent blood clots from sitting in the new opening, as they will rapidly turn into scar tissue. The cow should be milked as frequently as possible the first day to remove blood clots. In some cases, this is every 20 minutes for the first two hours, and then hourly for the rest of the day. If the silicone prosthesis is used, the cow is returned to normal machine milking (see notes on prosthesis below). Prognosis is guarded.

Nonexistent teat orifice : If the teat sphincter is intact (as determined by palpation and ultrasound), the skin may be lanced to open the sphincter. The cow must then be milked regularly and/or dilators used to keep the skin from scarring shut. However, if the teat sphincter is abnormal or nonexistent, we have no means of reconstructing it at this time.

Absent teat lumen : Rarely, a cow presents with no teat lumen (e.g. no mucosal lining). If the lesion extends to the distal or proximal ends of the teat, treatment is difficult and usually unrewarding. For central lesions (e.g. secondary to scarring), a teat prosthesis is indicated.

Silicone teat implants : These implants are hollow tubes of a nonreactive material designed to act as a stent to keep the teat open and allow milk flow. The silicone is measured to the length of the teat from the proximal aspect of the sphincter to just into the gland cistern. It is sutured in place with 3-4 sutures of nonabsorbable material (usually 2-0 nylon). The teat is closed over the implant in 2-3 layers. Generally the teat is not bandaged. In most cases they are left in permanently; however, they do not often function past one lactation.

The tube covers abnormal areas or areas of denuded mucosa to prevent the granulation tissue from growing across and closing the lumen. However, if the lesion is very proximal or very distal it is easy for granulation tissue to grow across the tube opening and again obstruct milk flow. If the teat wall is not strong (and many are primarily composed of scar tissue when the tube is inserted) it may not hold sutures and the implant may slip up into the gland. This often happens in the dry period. Once in the gland, the implant acts as a ball valve, intermittently

obstructing milk flow. If the tube does not fit well it may cause teat wall necrosis or obstruct milk from entering at its proximal end.

The implant is palpable (important for show consideration). The teat should not be hand stripped after the implant is placed or the sutures may tear free from the teat wall (e.g. no CMTs). Treatment with mastitis preparations or placement of a teat cannula should be done extremely carefully to prevent dislodging the implant. It may help to shorten the end of the treatment tube so that it does not reach the implant. The cows are put back on the machine milker after the incision has a chance to form a fibrin seal (6-8 hours after surgery).

Slow milkers

Milk flow may be slowed by intraluminal structures, extraluminal pressure or abnormality of the sphincter, usually secondary to scarring.

Intraluminal lesions

Lactoliths or intraluminal scarring or granulation tissue can either slow flow or cause intermittent flow by acting as ball valves. Most of these can be detected by careful palpation and verified by ultrasound or probing with a teat cannula. Contrast radiographs may help outline the lesion if it is still in question. Small obstructions, particularly lactoliths, may be crushed with hemostats and milked out. Ideally, the obstruction is removed and the mucosa closed over the defect. Without mucosal closure, granulation tissue and scarring tends to reform. Thelotomy is the recommended procedure at this time. The scarring or intraluminal object is removed and the mucosa sutured over the defect. If mucosa cannot be closed, a teat prosthesis should be considered, particularly for central defects. Many defects are distal and are likely secondary to blunt trauma affecting the teat sphincter. Recent work using theloscopy has also shown promise to remove these lesions with minimal trauma; however, we are unaware of any reports on mucosal closure using this technique. Finally, the obstructions may be removed or scarring cut through the teat orifice. A variety of special knives are available for this procedure. Obviously mucosal closure is impossible with this approach and it is easy to cause additional damage and/or not remove the lesion in its entirety.

Extraluminal compression

The most common form of compression is caused by abscessation of the teat wall. If the abscess does not communicate with the teat or gland, it can be drained or resected off the teat. Care needs to be taken to retain as much skin as possible to close the defect. Alternately plastic surgery may be used as would be in other areas (a flap may be taken from the udder, the skin stretched prior to the procedure, meshing used, etc).

Tight sphincter

If the sphincter is the primary problem, surgical correction is difficult. As mentioned, at this time we have no means of reconstructing the sphincter. The most common treatment is cutting the sphincter in 2-4 areas with a teat knife. This is done standing with tail restraint or sedation. The cuts should be made with a full udder so that the speed of milk flow can be assessed. No more than four cuts are recommended at one time. It is very easy to cause the teat to become leaky after the surgery. To remove blood clots, cows should be milked approximately every 20 minutes

for the first 2 hours, then every 2 hours for the rest of the day. In most instances the sphincter will rescar over time, making the fix temporary at best. An alternative is to force two cannulas into the sphincter for 24 hours in an attempt to dilate it.

Improper milk flow

In other cases, the teat sphincter is leaky, the teat develops a fistula secondary to trauma or surgery, or the cow has a webbed or fused teat. Occasionally supernumerary teats are not removed at calthood and can interfere with milking.

Leaky teats

If the teat sphincter does not function properly, treatment is usually unrewarding. Attempts have been made to create scarring of the sphincter in order to tighten it up. This could include injections of a sclerosing agent or slight cutting of the sphincter. However, getting just the right amount of closure is very difficult. In many instances the best alternative is to dry off the quarter.

Sometimes the teat is injured to the extent that it must be removed due to trauma or infection. In these cases the quarter should also be dried off.

Drying off the quarter : If the teat or gland does not leak, simply stopping milking will cause cessation of milk flow. The quarter should be treated with a dry cow mastitis preparation prior to drying off. The quarter will usually resume milking on the next lactation. If the quarter needs to be dried off more permanently or if milk leakage occurs, chlorhexidine (20-30cc) is injected into the quarter and, if possible, the area of leakage sealed at least temporarily.

Milk fistulas

These can occur secondary to lacerations or surgery or may be congenital (usually associated with other teat anomalies). As mentioned previously, they should be resected using a full thickness incision and the opening closed in three layers as for a laceration. Good mucosal closure is critical. It has generally been recommended to treat these in the dry period. However, waiting increases the risk of mastitis and lowers milk yield. Doing surgery in the dry period means mammary defenses are at a low point and there may be additional risks if the cow is heavily pregnant. These can be successfully treated in the milking cow. Bandaging may help minimize pressure on the incision; however, this is a difficult area to bandage. Elasticon tape over a regular bandaid or small gauze may hold but will need frequent checking and replacement. In lactating animals regular machine milking will help remove the edema and eliminate the need for a bandage. Mastitis is a frequent complication.

Webbed teats and fused teats

Occasionally congenital lesions occur wherein one gland is drained by two teats or is subdivided into two areas, each with their own teat. Unfortunately, neither works well with modern equipment. Ultrasound, contrast radiography, or injection of new methylene blue may be useful to determine potential connections. If the gland is subdivided, the teat supplying the larger area is obviously the one that should be maintained. The second should be treated as a fistula and closed over. If possible, a connection between the two portions of the gland should be made to allow

maximum milk flow and to prevent a lopsided udder appearance. However, depending upon the level of the connection, this can be difficult.

Supernumerary teats

These are best removed in the young calf. Burdizzos, scissors or a scapel may be used. The cut should be made in a cranial-caudal direction so that scars will merge with the skin folds. A single suture may be required.

Preoperative and postoperative care for teat surgery : We generally recommend culturing the affected quarter prior to surgery, particularly if an implant is to be used. Most cows are given ceftiofur prior to surgery and may or may not be continued on postoperative antibiotics (either systemically or intramammary). Flunixin meglumine may be given to decrease postoperative swelling. Studies have shown that machine milking is actually less traumatic than handmilking, so most cows are returned to machine milking following surgery, once a fibrin seal has had a chance to form (after 6-8 hours). Generally, one milking of the affected teat is skipped. Bandages are difficult to place on teats and may hold in moisture and contamination. Leaving a wound open allows drainage. Routine premilking preparation will clean the area. Avoid topical medications : these can enter the milk supply and generally do not speed healing in this area. As an exception, first calf heifers with an abrasion injury may better tolerate the milker if a non-irritating salve is first applied.

Anesthesia: Most of these procedures are done with the cow restrained in dorsal recumbancy. Cows not in late gestation can be sedated with xylazine. Other options include acepromazine and butorphanol. Local anesthesia is provided by a ring block around the base of the teat and intraluminal lidocaine administered via a teat cannula. General anesthesia is generally indicated for udder amputations.

Milk vein problems

The most common problems associated with the milk vein are lacerations and abscesses (usually secondary to injections). Lacerations of the milk vein can be rapidly fatal. Pressure should be applied to the area as soon as possible and the laceration sutured closed or a bandage sutured to the area to maintain pressure until the hemorrhage stops. The cow should be monitored closely over the next several hours to ensure hemorrhage does not resume. The bandage can be removed after 2-3 days. Soaking the bandage with water or saline prior to removal will prevent removing the clot along with the bandage.

Abscesses are usually walled off from the areas of blood flow by the time of diagnosis. However, confirmation using ultrasound and a large gauge needle are advised. If only pus exits the needle, it should be safe to lance in that area. We often use 2-3 needles to ensure that there is room to make a cut without entering patent vein. The abscess should be opened wide enough to allow digital palpation. The incision can then be safely enlarged to allow optimum drainage.

Surgery of the gland

The gland itself only occasionally requires treatment. Primary reasons for surgery include lacerations and infections. Lacerations of the gland bleed heavily and should be treated as for milk vein lacerations. If the duct system is entered, milk fistulas and/or mastitis may result.

Occasionally, half of the udder or the entire udder must be removed. This may be to salvage a cow with nonresponsive mastitis, extreme loss of suspensory apparatus or neoplasia as an embryo donor or for slaughter. It is a more common procedure in goats (mastitis, hermaphrodites, or trauma). Mastectomy is best performed under general anesthesia due to the very vascular nature of the surgery and the difficulty in obtaining good local anesthesia without limb paralysis.

References

Bristol DG. Teat and udder surgery in dairy cattle- Part I. *Comp Cont Educ Pract Vet* 11:868-873, 1989.

Bristol DG. Teat and udder surgery in dairy cattle - Part II. *Comp Cont Educ Pract Vet* 11:983-988, 1989.

Geishauser T, Querengässer K, Medl M. Covered teat canal injuries in dairy cows. *Comp Cont Educ Pract Vet* 20:S251-S257, 1998.

Trostle SS, O'Brien RT. Ultrasonography of the bovine mammary gland. *Comp Cont Educ Pract Vet* 20:S64-S71, 1998.

Hull BL. Teat and udder surgery. *Vet Clin N Amer: Food Animal Pract* 11(1):1-17, 1995