

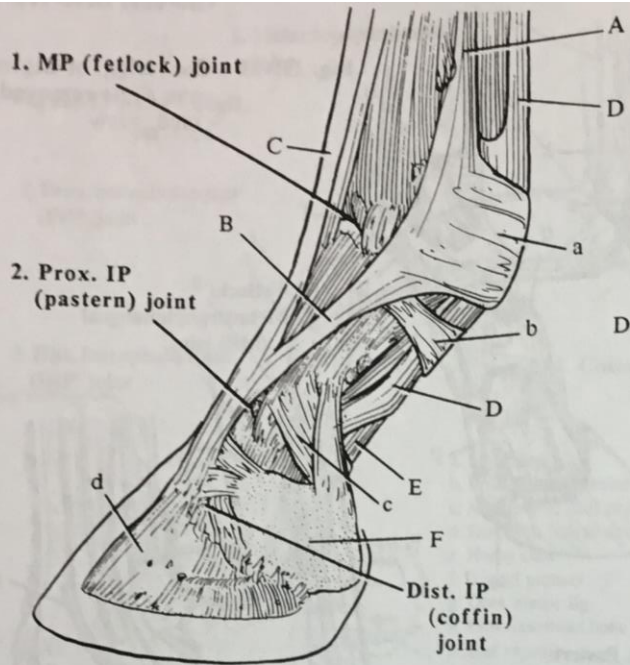Fig. III-23 - Horse - Digit - lat. view

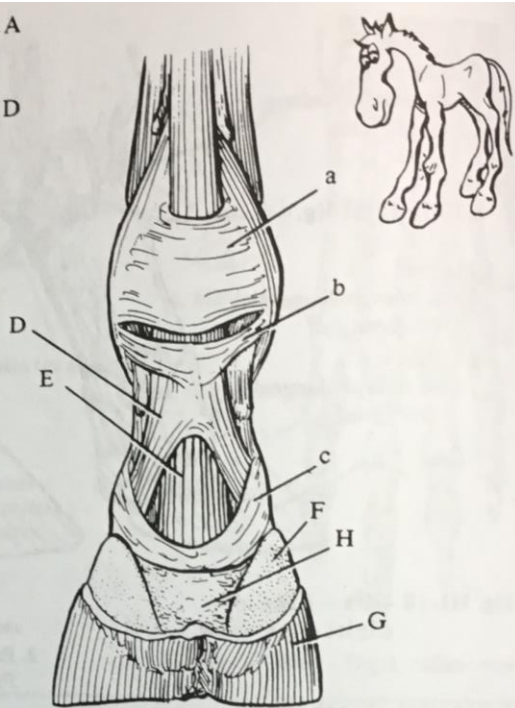


Fig. III-24 - Horse - Digit - palm. view

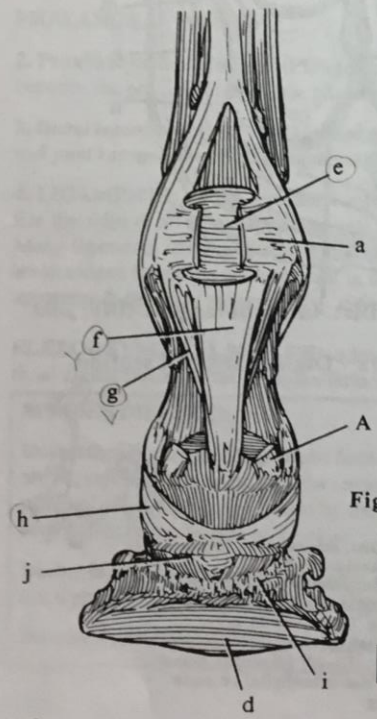


Fig. III-25 - Horse - Digit, supf. & deep digital flexor tendons removed - palm. view

Radiography: pg. 638

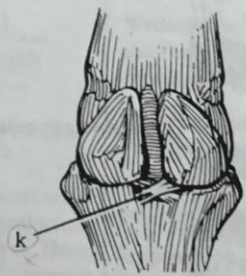


Fig. III-26 - Horse - Fetlock joint - palm. view

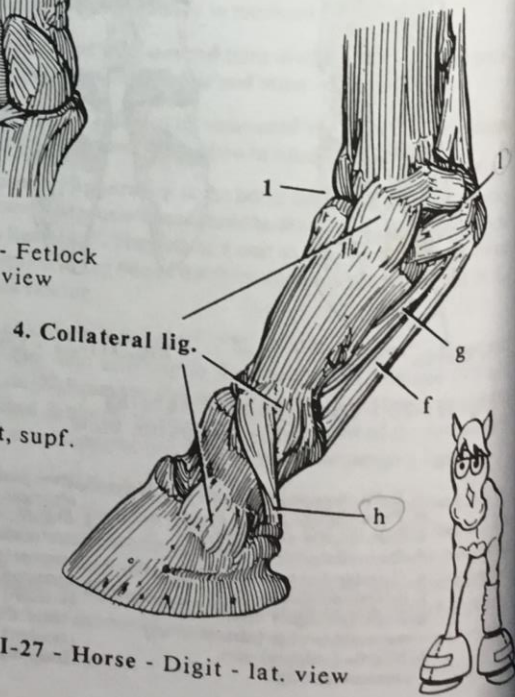


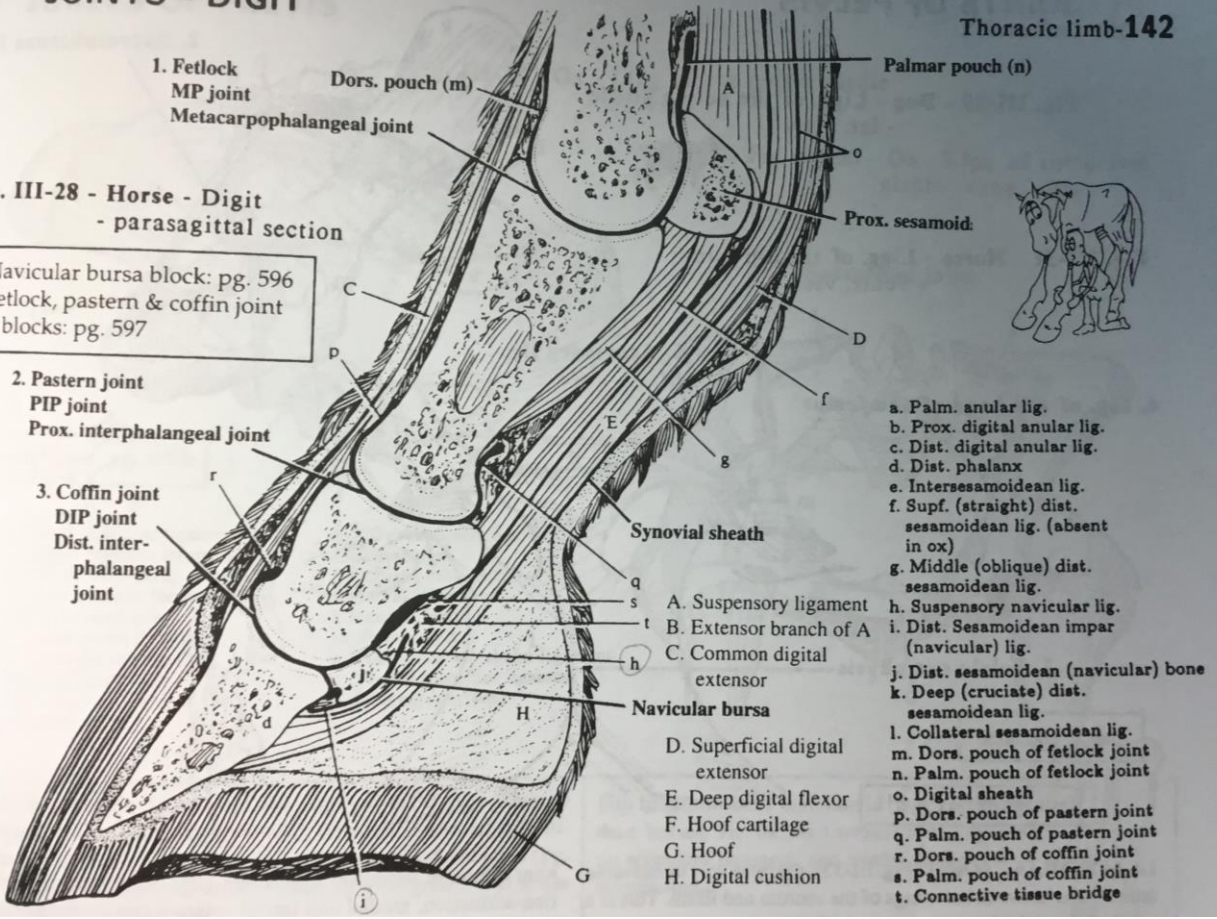
Fig. III-27 - Horse - Digit - lat. view

JOINTS - DIGIT

Thoracic limb-142

Fig. III-28 - Horse - Digit
- parasagittal section

Navicular bursa block: pg. 596
Fetlock, pastern & coffin joint
blocks: pg. 597



1. Fetlock
MP joint
Metacarpophalangeal joint

2. Pastern joint
PIP joint
Prox. interphalangeal joint

3. Coffin joint
DIP joint
Dist. interphalangeal joint

Dors. pouch (m)

Palmar pouch (n)

Prox. sesamoid

Synovial sheath

Navicular bursa

- A. Suspensory ligament
- B. Extensor branch of A
- C. Common digital extensor
- D. Superficial digital extensor
- E. Deep digital flexor
- F. Hoof cartilage
- G. Hoof
- H. Digital cushion

- a. Palm. annular lig.
- b. Prox. digital annular lig.
- c. Dist. digital annular lig.
- d. Dist. phalanx
- e. Intersesamoid lig.
- f. Supf. (straight) dist. sesamoid lig. (absent in ox)
- g. Middle (oblique) dist. sesamoid lig.
- h. Suspensory navicular lig.
- i. Dist. Sesamoid impar (navicular) lig.
- j. Dist. sesamoid (navicular) bone
- k. Deep (cruciate) dist. sesamoid lig.
- l. Collateral sesamoid lig.
- m. Dors. pouch of fetlock joint
- n. Palm. pouch of fetlock joint
- o. Digital sheath
- p. Dors. pouch of pastern joint
- q. Palm. pouch of pastern joint
- r. Dors. pouch of coffin joint
- s. Palm. pouch of coffin joint
- t. Connective tissue bridge



Fig X-50.

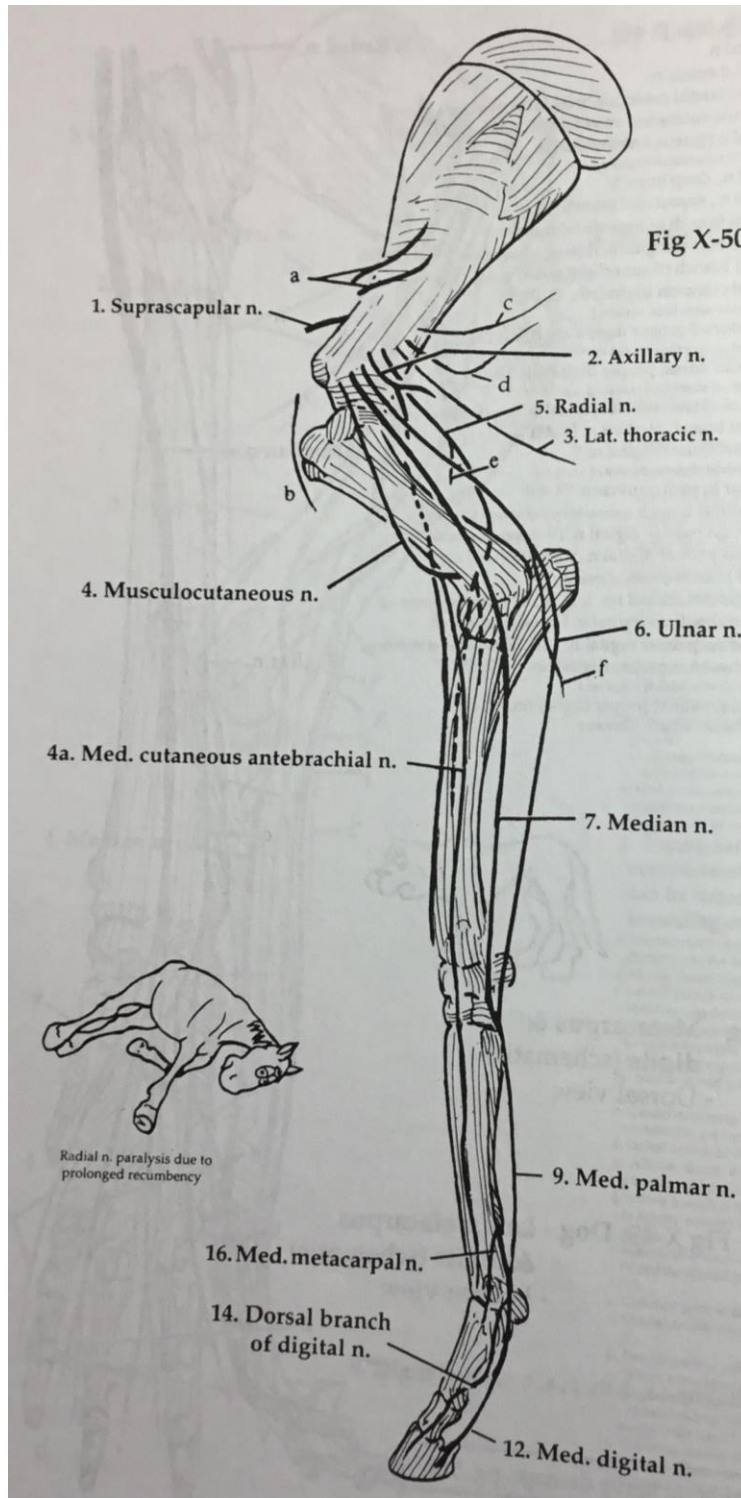
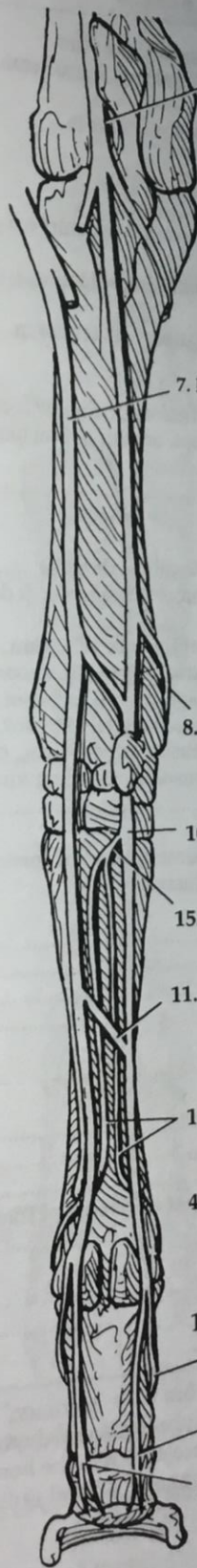


Fig X-52: Horse - Right forearm & manus (schematic) - Palmar view



6. Ulnar n.

7. Median n.

8. Dorsal branch of ulnar n.

10. Lat. palmar n.

15. Deep branch of lat. palmar n.

11. Communicating branch

17. Lat. & med. metacarpal nn.

4a. Med. cutaneous antebrachial n.

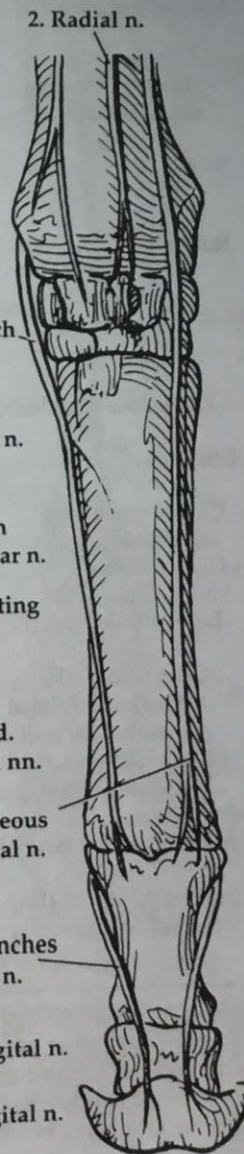
14. Dorsal branches of digital n.

13. Lat. digital n.

12. Med. digital n.

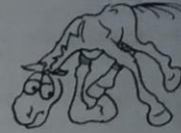

Fig X-51: Horse - Right manus (schematic) - Dorsal view



2. Radial n.

8. Dorsal branch of ulnar n.

17. Lat. & med. metacarpal nn.

14. Dorsal branches of digital n.

13. Lat. digital n.

All images taken from Pasquini C, Spurgeon T. Anatomy of domestic animals. 11th ed. LaPorte, CO: Sudz Publishing; 2007.