



John Matthews qualified from the University of Glasgow in 1975. He is past president of the Goat Veterinary Society (GVS), honorary veterinary surgeon for the British Goat Society and has kept, bred and shown dairy goats for 30 years. He regularly lectures on goats at the University of Cambridge veterinary school.



Ben Dustan qualified from the University of Liverpool in 2007. He owns a farm animal practice in the Lake District and is currently honorary secretary of the GVS, providing much of the GVS's advice and support. He lectures on goats nationally.

Disbudding of goat kids

Background: Disbudding is the most common surgical procedure carried out in goats, but the relatively small number of these animals in the UK means that many veterinary students will leave university without ever having seen a kid disbudded. Goat keepers regularly comment on the poor technique of practitioners when undertaking disbudding, which results in a failure to remove the horn buds completely or even the deaths of kids.

Aim of the article: This article provides veterinary surgeons with the information required for the safe and successful disbudding of kids. It is worth noting that the procedure for the disbudding of goat kids is very different from that for disbudding calves.

Reasons for disbudding

Disbudding of kids is defined as a mutilation under the law in England, Wales, Scotland and Northern Ireland, but it is recognised as a procedure that can be carried out for non-therapeutic reasons. Not all goats are disbudded; many pygmy goats and Boer goats are kept horned, and Angora and Cashmere goats are never disbudded. However, most dairy kids kept on smallholdings and in commercial herds are routinely disbudded. To justify the routine disbudding of dairy kids, it needs to be demonstrated that there are legitimate reasons for the procedure.

In the wild, horns may help to protect a goat from smaller predators, assist the regulation of body temperature in hot climates and help individual animals establish dominance within a herd's hierarchy. It is the dominance aspect that causes most problems within goat herds kept in fairly close confinement (eg, many dairy herds). Horned goats know how to use their horns to best advantage during regular tussles with other goats and will hook with a goring action, which often damages udders in particular and, occasionally, other parts of the body, such as the eyes and

eyelids. Damage from horns can also occur during transportation.

Goats are generally friendly animals (intentional injuries to people are uncommon), which leads to close contact with people and the risk of accidental damage from an animal's horns if it brings its head up suddenly or turns unexpectedly, for example, while being milked. Children's faces and eyes are especially at risk. The RSPCA recommends that novice owners keep hornless rather than horned goats, particularly in the case of the larger breeds, as horns can make goats more difficult to handle and may be less suitable if children are helping to care for them (RSPCA 2019).

Disbudding can also prevent goats harming themselves. Horned goats regularly get stuck in fences and hedges; as most dairy goats' horns point backwards, they are able to get their heads through relatively small gaps but then cannot withdraw them because the horns get stuck. Occasionally ingrowing horns can dig into an animal making it necessary to dehorn an adult goat; this is a much more serious and invasive surgical procedure than disbudding.

Disbudding goats as kids does not alter their behaviour, except possibly by making them less aggressive to other goats. They will still fight to establish dominance, bashing heads using the thick bone plates of the forehead and engaging in jostling matches as they establish the pecking order within a herd. However, disbudded goats are at a distinct disadvantage if challenged by a horned goat, so goats without horns should never be kept with horned goats.

Polled goats

In some cattle breeds it is possible to breed hornless animals and thus avoid the need for disbudding. Unfortunately, this is not possible in goats. After the Second World War, the British Goat Society tried

doi: 10.1136/inp.l6028

KEY LEARNING OUTCOMES

After reading this article, you should:

- Understand the reasons for disbudding kids;
- Be able to select a suitable anaesthetic regimen for disbudding kids in the surgery or on the farm;
- Be able to decide on the most suitable equipment to use in different situations;
- Be able to follow the safe anaesthetic and surgical procedures for disbudding kids;
- Be aware of the problems that may occur when disbudding kids and understand how to avoid them.

Farm animals

to encourage the breeding of polled goats by only allowing the registration of polled males. This led to many more polled goats in the country and it soon became apparent that the genes for hornlessness were associated with a recessive gene for intersex. An intersex is an animal that shows both male and female characteristics, and is generally a polled goat with two polled parents. A mating between a homozygous (PP) polled male and a heterozygous (Pp) polled female will produce 50 per cent intersexes; a mating between a heterozygous (Pp) polled male and a heterozygous (Pp) polled female will produce 25 per cent intersexes. In theory, mating two homozygous (PP) polled animals should produce 100 per cent intersexes, but this level is never reached as the gene has incomplete penetrance.

Legislation

In the UK, the disbudding and dehorning of goats is considered veterinary surgery under the provision of the Veterinary Surgeons Act 1966, amended in 1982, so can only be undertaken by a veterinary surgeon. The one exception is trimming of the insensitive tip of an ingrowing horn, which, if left untreated, could cause pain or distress. Secondary legislation in the UK does not specifically require an anaesthetic to be administered when disbudding goats. However, disbudding should be carried out in accordance with good practice so that pain and suffering is minimised, and should include anaesthesia (Anon 2012).

Goats are considered to be a 'food-producing species.' There is no legal provision for 'pet' goats and therefore the legislation concerning drug use for food-producing species applies irrespective of whether an individual animal is being kept with the intention of producing meat or milk for human consumption. As there are few drugs specifically licensed for use in goats, it is generally necessary to use those licensed for use in other species of farm animals and the provisions of the prescribing cascade apply. Although meat withdrawal periods are unlikely to be relevant to kids, it is advisable to refer to guidance from the Veterinary Medicines Directorate (VMD) (2019) and BVA (2019).

Age at disbudding

Horn buds in goat kids are proportionally much larger than in calves, so the recommended age for disbudding is two to seven days rather than the four weeks for calves. At this age the buds are small enough to remove with one application of the disbudding iron. The removal of overlarge buds with the iron from kids that are presented at an older age should not be attempted as it is stressful for both the animal and the veterinary surgeon, and the bud will often regrow. In such cases it is preferable to wait until the horns are large enough for removal with embryotomy wire.

BOX 1: ESSENTIAL FACTORS ENABLING SAFE DISBUDDING

- Short time away from the mother
- Short time in the surgery
- Short-acting anaesthetic
- Rapid recovery
- Weighing of kids if injectable drugs are being used for induction
- Very hot disbudding iron
- Short time of application of the iron
- Large enough diameter head on the iron (minimum 2 cm)
- Horn buds small enough to remove with one application of the iron
- Provision of a warm, dry and draught-free environment for the kids before, during and after disbudding

Safe disbudding


The essential elements for successful and safe disbudding, which are the same whether carried out on farm or in the surgery, are listed in Box 1.

Possible adverse outcomes of disbudding are listed in Table 1.

Anatomy

The distribution of nerves to the horns is described in Box 2. If local anaesthetic injections are used to desensitise the horn buds, the cornual branch of the lacrimal nerve must be blocked (as with calves), but it is also essential to block the cornual branch of the infratrochlear nerve. This means that relatively large amounts of local anaesthetic are required in a very

Table 1: Possible adverse outcomes of disbudding

Adverse outcome	Cause
Regrowth of horns resulting in unsightly scurs 	Poor technique, buds are too large as the kid is too old
Prolonged recovery time	Anaesthetic overdose
Disbudding meningoencephalitis	Prolonged application of the iron
Convulsions/seizures	Prolonged application of the iron
Fractured skull	Prolonged or overzealous use of the iron
Death	Anaesthetic overdose, hypothermia

Farm animals

BOX 2: ANATOMY OF A GOAT'S HORN

Two nerves supply each horn bud on a goat (Fig a):

- Cornual branch of the lacrimal nerve;
- Cornual branch of the infratrochlear nerve.

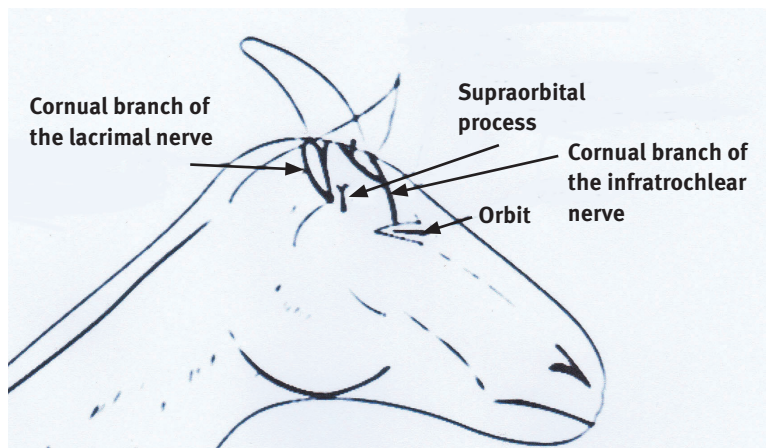


Fig a: Distribution of nerves to the horns of a goat

BOX 3: ANAESTHETIC DRUGS FOR USE IN FARM ANIMALS THAT ARE LISTED IN TABLE 1 OF REGULATION EU 37/2010

- Xylazine
- Detomidine
- Romifidine
- Isoflurane
- Ketamine (licensed in goats)
- Thiopental sodium
- Lignocaine/lidocaine
- Mepivacaine
- Procaine
- Butorphanol

small animal, so there is a danger that toxic levels might be reached.

Selection of anaesthetic agents

Best anaesthetic practice is not always in accordance with legislation governing the use of anaesthetic agents in farm animals. Veterinary surgeons should always remember that a kid is a neonate and, as such, will have a reduced ability to metabolise and excrete anaesthetic agents. The practical effect of the provisions of the prescribing cascade are that the active ingredient(s) of any medicine (including anaesthetics) used in goats must be listed in Table 1 of the EU Commission Regulation EU 37/2010 (EUR-Lex 2019). There is no legal provision for the use of many safe and effective anaesthetic agents, which may result in a conflict between clinical need and legislation. Products suitable for use in the anaesthesia of farm animals are listed in Box 3.

Ketamine is a Schedule 2-controlled drug and when used for general anaesthesia it is usually administered in combination with other agents that are unlikely to have marketing authorisations for goats in the UK. Currently, Anaestamine 100 mg/ml injection (Animalcare) is the only anaesthetic agent containing ketamine that is licensed in the UK for use in goats.

Anaesthetic administration

Anaesthetic can be administered using a mask or by intravenous injection or local infiltration.

Mask

Induction and maintenance with isoflurane in oxygen by mask is simple, quick and safe (Figs 1, 2)

and recovery is very rapid, but there are health and safety implications for staff. A close-fitting mask in a well-ventilated environment should be used and gas levels monitored. As oxygen supports combustion, the mask must be removed before disbudding if a gas disbudder is used.

Intravenous injection

Anaesthetic can be administered intravenously via the cephalic or jugular vein, but the latter is usually the most easily accessible.

Propofol at 3 to 5 mg/kg (3 to 5 ml/10 kg bodyweight) and alphaxalone (10 mg/ml) at 4.5 mg/kg (4.5 ml/10 kg), both given slowly intravenously, have been used to induce anaesthesia, but neither drug is licensed for use in food-producing animals.

Local infiltration

Like all neonates, kids are very sensitive to procaine and lidocaine (analgesic doses are very close to toxic doses) and an overdose will result in lethargy, unwillingness to feed and even death. The toxic dose is about 10 mg/kg; that is, 2 ml of 2 per cent lidocaine or 0.8 ml of 50 mg/ml procaine for a 4 kg kid.

Two nerves supply each horn bud, as shown in Box 2. The cornual branch of the lacrimal nerve should be blocked between the lateral canthus of the eye and the posterior aspect of the bud, using the supraorbital process as a landmark. The cornual branch of the infratrochlear nerve should be blocked dorsomedial to the eye, close to the orbit. Sterile water (3 ml) should be added to 1 ml of 50 mg/ml procaine + adrenaline (Adrenocaine; Norbrook Laboratories) to give 4 ml of procaine, then a maximum of 1 ml of diluted procaine used at each site.

Farm animals

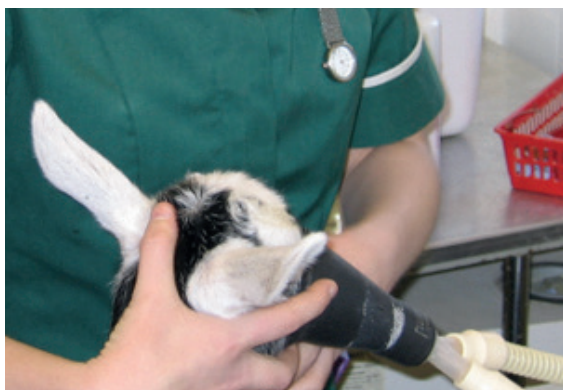

Fig 1: Anaesthetic induction by mask

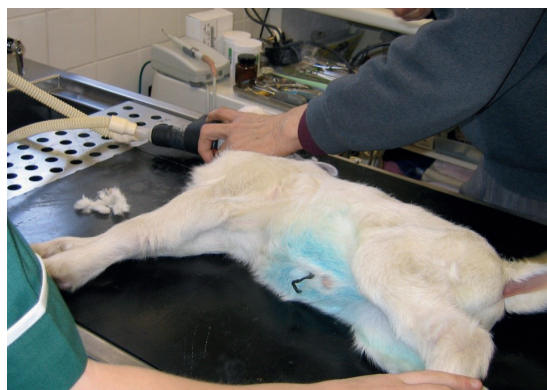

Fig 2: Anaesthesia by mask for disbudding in the surgery

Alpha-2 agonists

Xylazine is the most common α 2-agonist that is used as an anaesthetic for disbudding kids. Unless reversed with atipamezole (which is not legally allowed in the UK) it produces prolonged recumbency and because very small amounts are required it is very easy to overdose a kid, sometimes with fatal consequences.

The ruminant dose is much less than that routinely used in dogs and cats, and it is preferable to dilute the standard 2 per cent solution with sterile water and administer it with an insulin syringe to allow more accurate dosing. For goats, 0.05 mg/kg (0.01 ml/10 kg) xylazine (2 per cent solution) should be administered intravenously or 0.025 mg/kg (0.02 ml/10 kg) intramuscularly.

Disbudding in the field

It is acceptable and possible to disbud goat kids out on farm, and when there are large numbers of kids to disbud in a session this is often preferable. It allows the kids to recover in their familiar rearing environments, they are able to milk feed as soon as they are able to stand and they do not have to be transported between the surgery and the farm before and after the surgical event. On larger dairy units within the UK it is not uncommon to have a weekly disbudding visit where tens of kids will be disbudded on farm each session during the kidding period. Relatively frequent visits may be required to ensure that the kids presented for disbudding are of a suitable age and have a small enough bud for successful disbudding.

The key to on-farm disbudding is the preparation of the disbudding environment and knowledge of the potential complications of the procedure so that mitigating actions can be put in place to reduce risks and avoid complications.

It is likely that the most practical and safest route to provide anaesthesia while carrying out on-farm disbudding is by injection. To remain within the law, probably the most appropriate anaesthetic regimen is a combined solution of ketamine, xylazine and butorphanol (KXB kid mixture) as described in Box 4. Xylazine can be combined with

ketamine and butorphanol to produce a mixture that can be used on farm when groups of kids need disbudding. The small amount of mixture required means use of an insulin syringe for accurate measurement is essential and kids should be weighed beforehand as necessary.

In the field, we prefer to have all kids for disbudding within a clean, draught-free, dry building, with ample light and heat lamps for the animals during anaesthesia and recovery. Anaesthetic is administered to between three and five kids in succession and they are then placed under the heat lamps until they become fully anaesthetised (Fig 3). In cold weather, blankets or clean towels arranged around and over the kids will ensure that hypothermia is not a problem. Once disbudded, the kids are returned to the heat lamp and nest of blankets (if provided) to fully recover.

Analgesia

The Goat Veterinary Society (GVS) recommends that all kids being disbudded are given supplementary analgesia. Most veterinary surgeons use an injectable non-steroidal anti-inflammatory agent such as meloxicam, which, at 0.5 mg/kg, has been shown to reduce pain for the first 24 hours after disbudding when compared to untreated kids (Ingvast-Larsson and others 2011). However, goat keepers should be informed that there are no analgesics licensed for use in goats in the UK and no analgesics licensed for any animal of only a few days of age; they should therefore be asked to sign a consent form to show that they are aware that the drugs are being used 'off-licence'. In a GVS survey

BOX 4: KETAMINE, XYLAZINE AND BUTORPHANOL (KXB) KID MIXTURE

1000 mg ketamine : 20 mg xylazine : 10 mg butorphanol
 10 ml ketamine (100 mg/ml) + 1 ml xylazine (20 mg/ml) +
 1 ml butorphanol (10 mg/ml)

To a 10 ml bottle of ketamine, add 1 ml xylazine 2 per cent solution and 1 ml butorphanol. The solution is administered at 0.1 ml/5 kg intravenously via either the cephalic or jugular vein.



Fig 3: Anaesthetised kids awaiting disbudding on farm

of veterinary surgeons disbudding around 2000 kids per year between them and routinely using analgesics, no adverse reactions were reported.

Intravenous butorphanol (0.2 mg/kg) has also been used in kids and provides analgesia for over two hours.

Equipment

Calf disbudding irons are adequate for disbudding small kids provided they reach a satisfactory temperature and have a large enough diameter head (minimum 2 cm, preferably 2.5 cm or 2.8 cm for male kids). Gas irons are probably better than electric irons, but the latter can be used effectively and are safer if gaseous anaesthesia is being used. Dehorning irons heated in a gas blowtorch to 600°C are also suitable. The GVS can provide modified calf disbudding copper irons that have been specifically remodelled for the disbudding of goat kids. These irons require a separate heat source/gas cylinder (Fig 4).

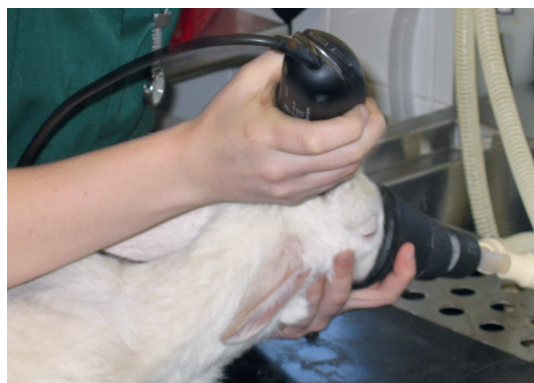

Fig 5: Clipping hair with electric clippers



Fig 4: Disbudding iron being heated by a blowtorch

Cautery disbudding procedure

- Clip the hair from around the horn bud with clippers or scissors (Figs 5, 6).
- With larger buds, clip off the tips of the buds using scissors or bone forceps if necessary (Fig 7).
- Apply the iron to the bud with an even action to ensure the whole bud tissue is destroyed. It is important to use a very hot iron for the minimum time necessary to remove the bud. The heat of the iron rather than pressure destroys the bud. Excessive pressure or prolonged application of the iron may result in cortical necrosis, cerebral oedema and a brain-damaged kid, or even a skull

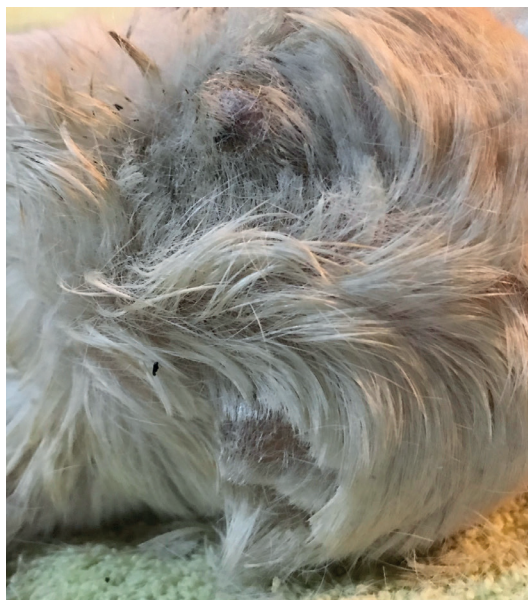

Fig 6: Horn buds exposed by clipping with scissors

Farm animals

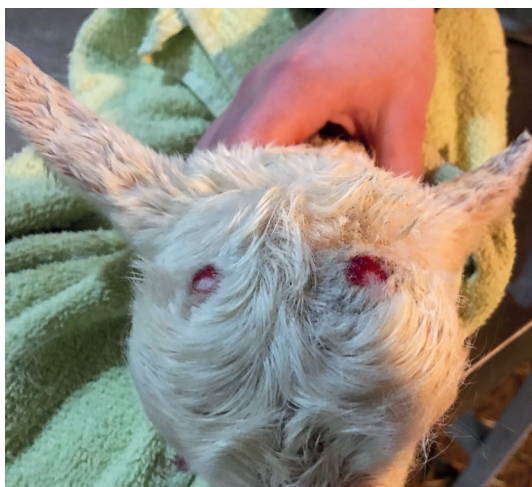

Fig 7: Horn bud tips have been removed to allow direct contact of the iron with the skull

fracture. Avoid prolonged application of the hot iron to the skull. It is better to apply the iron for two to three seconds at a time, followed by two to three seconds off the skull, repeating as necessary until the horn bud can be removed.

- Remove the whole bud rather than just burn around it, as this reduces the risk of infection (Fig 8).
- If the disbudding iron has a recessed head or the iron is not very hot, scrape the burned out area with a scalpel blade and then briefly reapply the iron to ensure the tissue is destroyed.
- If the cauterised area is not large enough, remove a further ring of tissue by carefully reapplying the iron or use an electric cauterly knife or scalpel

blade. Several superficial vessels, especially the superficial temporal artery on the lateral side of the horn, may require recatherising.

- Spray the cauterised areas with a tetracycline spray or a natural camomile/powderising spray (eg, SCP spray; Derbymed) (Fig 9) to reduce the chances of infection.
- Parenteral antibiotics should not be necessary.
- If the kid's immune status is questionable or unknown, or if it is over four weeks old, 250 to 300 iu of tetanus antitoxin (Tetanus Antitoxin Behring; MSD Animal Health) should be given at the time of disbudding.
- Keep the kids warm, dry and draught-free during their recovery and observe them regularly, making sure they have an unobstructed airway.

Alternative methods

Alternative methods to cautery disbudding have been suggested and involve the use of caustic paste, liquid nitrogen or the injection of clove oil into the horn bud (Hempstead and others 2018), but all appear to have disadvantages. Caustic paste can cause damage to other kids and the dam. Liquid nitrogen disbudding appears to be more painful than the cautery procedure. Injecting clove oil into the horn buds appears to be effective in preventing horn growth, but its legality is questionable in the UK and therefore it is not recommended.

Summary

Of all the domestic species, only kids are routinely anaesthetised so soon after parturition. Because they are alert, active and relatively large when compared to, say, an adult cat, it is easy for

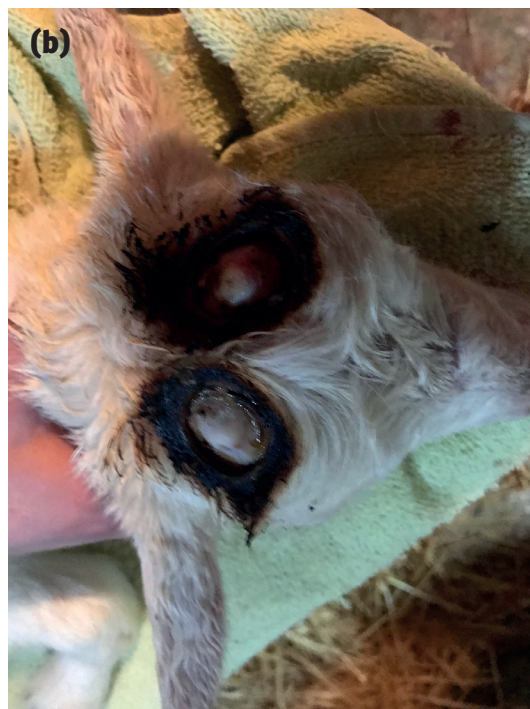
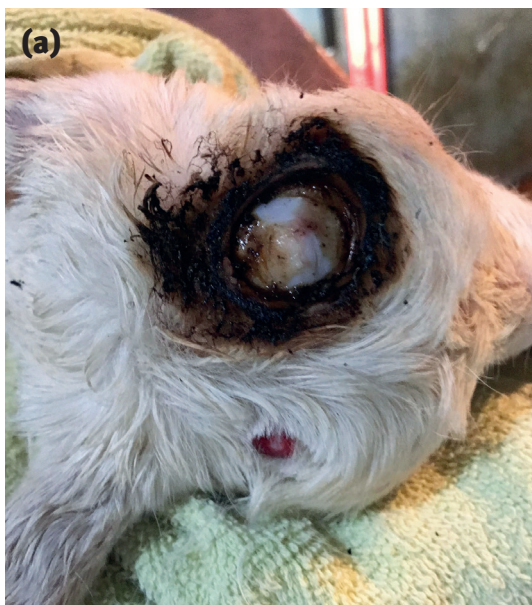
Fig 8: Kid with (a) the left-hand side horn bud removed and (b) both horn buds removed

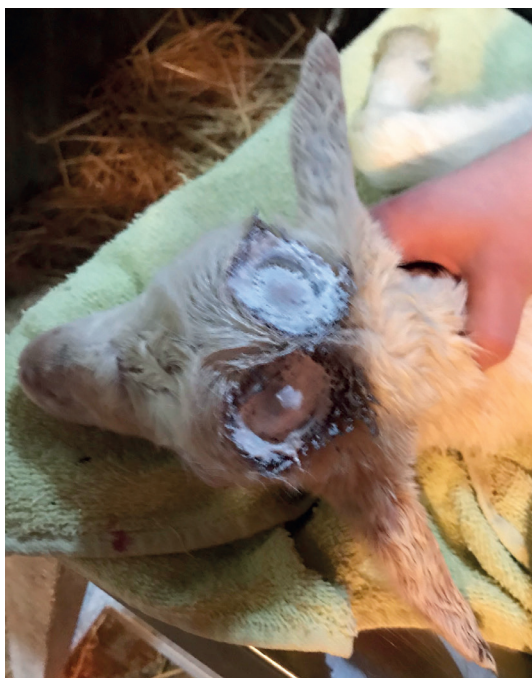

Fig 9: Kid that has had topical spray applied to the cauterised area immediately after disbudding

veterinary surgeons to forget that they are dealing with a neonatal animal. As with all surgical procedures, basic preparation and planning beforehand (how is the kid to be handled before, during and after surgery) will reduce risk to the animal. Familiarisation with the disbudding technique, administration of short-acting anaesthetic agents and the use of suitable equipment will all help to ensure a successful outcome. Wherever possible, growing kids should be examined a month or so after disbudding to determine whether the whole horn bud has been removed or if there is regrowth of horn and scur formation.

This article aims to help veterinary surgeons with the disbudding of goat kids, but it is still advisable that inexperienced practitioners observe the procedure being carried out by an experienced surgeon initially and then, wherever possible, disbud their first kids under supervision.

References

- ANON (2012) RCVS clarifies legal position on disbudding goats. *Veterinary Record* 171, 186
- BVA (2019) Veterinary medicines good practice guide. www.bva.co.uk/Workplace-guidance/Medicines/veterinary-medicines-good-practice-guide/. Accessed October 12, 2019
- EUR-LEX (2019) Table 1. Commission Regulation (EU) No 37/2010 of 22 December 2009 on pharmacologically active substances and their

KEY POINTS

Key point 1

Kids are the youngest animals most veterinary surgeons ever anaesthetise. Because they are alert, active and relatively large when compared to, say an adult cat, it is easy for the practitioner to forget that they are dealing with a neonatal animal.

Key point 2

Local nerve blocks can be used for anaesthesia, but great care must be taken to avoid overdosing. Other methods of anaesthesia are preferable.

Key point 3

- The majority of anaesthetic deaths in kids are caused by xylazine overdose.
- Be careful not to confuse 2 per cent and 10 per cent solutions of xylazine.
- Minute doses of xylazine are required in young animals and it is very easy to overdose.
- In kids, 0.025 mg/kg xylazine given intramuscularly is probably the maximum safe dose.

Key point 4

Take time to re-examine older kids to determine the success of your disbudding technique.

- classification regarding maximum residue limits in foodstuffs of animal origin. <https://eur-lex.europa.eu/legal-content/EN/TXT/?uri=CELEX%3A32010R0037#document1>. Accessed October 12, 2019
- HEMPSTEAD, M. N., WAAS, J. R., STEWART, M., CAVE, V. M. & SUTHERLAND, M. A. (2018) Evaluation of alternatives to cautery disbudding of dairy goat kids using physiological measures of immediate and longer-term pain. *Journal of Dairy Science* 101, 5374-5387
- INGVAST-LARSSON, C., HÖGBERG, M., MENGISTU, U., OLSÉN, L., BONDESSON, U. & OLSSON, K. (2011) Pharmacokinetics of meloxicam in adult goats and its analgesic effect in disbudded kids. *Journal of Veterinary Pharmacology and Therapeutics* 34, 64-69
- RSPCA (2019) Goats. Introduction to Welfare and Ownership. www.rspca.org.uk/adviceandwelfare/farm/farmanimals/goats. Accessed October 12, 2019
- VMD (2019) Record keeping requirements for veterinary medicines. www.gov.uk/guidance/record-keeping-requirements-for-veterinary-medicines. Accessed October 12, 2019

Further reading

- BVA (2018) BVA and Goat Veterinary Society policy position on goat kid disbudding and analgesia. www.bva.co.uk/uploadedFiles/Content/News,_campaigns_and_policies/Policies/Ethics_and_welfare/goat%20disbudding.pdf. Accessed October 18, 2019
- GOAT VETERINARY SOCIETY (2018) Should we disbud and castrate goat kids? www.goatvetsoc.co.uk/wp-content/uploads/2017/08/Should-we-disbud-and-castrate-kids-250218.pdf. Accessed October 24, 2019
- HEMPSTEAD, M. N., STEWART, M., WAAS, J. R. & SUTHERLAND, M. A. (2016) A physiological evaluation of the efficacy of pain-mitigation strategies for cautery-disbudded goat kids. www.nzsap.org/system/files/proceedings/%2318%20Hempstead.pdf. Accessed October 12, 2019
- MATTHEWS, J. (2016) Disbudding and dehorning. In *Diseases of the Goat*. 4th edn. Wiley Blackwell. pp 359-363

Farm animals

SELF-ASSESSMENT: DISBUDDING OF GOAT KIDS

In Practice partners with BMJ OnExamination to host self-assessment quizzes for each clinical article. These can be completed online at inpractice.bmj.com

1. The most suitable age for disbudding kids is:

- a) Four weeks
- b) Two to seven days
- c) Two to six weeks
- d) Two months

2. For how long should the disbudding iron be applied to the goat kids skull?

- a) For as little time as possible
- b) For as long as it takes to remove the entire bud
- c) For sequential bursts of no more than two to three seconds, avoiding prolonged application of the hot iron
- d) Until the kid begins to move

3. What are the main complications of applying the disbudding iron for too long to the goat kids skull?

- a) Thermocautery burn of the brain
- b) Skull fracture
- c) Hypothermia
- d) All of the above

4. Who is legally allowed to disbud goat kids in the UK?

- a) Any competent person, provided the goat kid is less than one month of age
- b) Any competent person, provided local anaesthesia has been given
- c) Any qualified veterinary surgeon
- d) Any qualified veterinary nurse

5. A recently disbudded goat kid has been brought back to the surgery with some horn regrowth. What are the most likely reasons for this to have occurred?

- a) Kid was too old/horn buds too large at initial disbudding
- b) Disbudding iron diameter too small
- c) Poor disbudding technique
- d) Any or all of the above

Answers: (1) b, (2) c, (3) a and b, (4) c, (5) d

Interested in goats? Check out these other articles from *In Practice's* archive

Skin diseases in goats

Skin diseases are common in UK goats. The trade in animals and animal products has also resulted in incursions of novel diseases into Europe, some of which are potential threats to goat herds in the UK. This article focuses on diseases that occur commonly, those presenting particular diagnostic or therapeutic difficulties, and those that appear to be current threats to the UK goat herds.

inpractice.bmj.com/content/40/4/149

Goat health planning

Although the veterinary profession has been at the forefront of ensuring that health planning is now widely adopted in the farm animal sector; it is not something that is regularly undertaken in the goat sector. This article describes the areas that should be considered when constructing a health plan for goats.

inpractice.bmj.com/content/38/8/387

Parasites of goats

Goats share a number of diseases in common with sheep and cattle and this is particularly true with regard to parasitic infections. The most important endoparasitic diseases seen in goats are parasitic gastroenteritis and coccidiosis. Ectoparasites may be found either permanently on goats (eg, mites and lice) or only when they come to feed (eg, ticks and flies). This article discusses the pathogenesis, diagnosis and control of the major endo- and ectoparasitic infections of goats.

inpractice.bmj.com/content/24/2/76



CORRECTION

MATTHEWS, J. & DUSTAN, B. (2019) Disbudding of goats. *In Practice* 41, 433-443 (doi: 10.1136/inp.l6028)

On page 438, the stated doses for xylazine were given as: 0.05 mg/kg (0.01 ml/10 kg) xylazine (2 per cent solution) should be administered intravenously or 0.025 mg/kg (0.02 ml/10 kg) intramuscularly.

This should read: 0.0125 mg/kg (0.005 ml/10 kg) xylazine (2 per cent solution) should be administered slowly intravenously or 0.025 mg/kg (0.01 ml/10 kg) intramuscularly.

The error is regretted.