



Nerve Supply

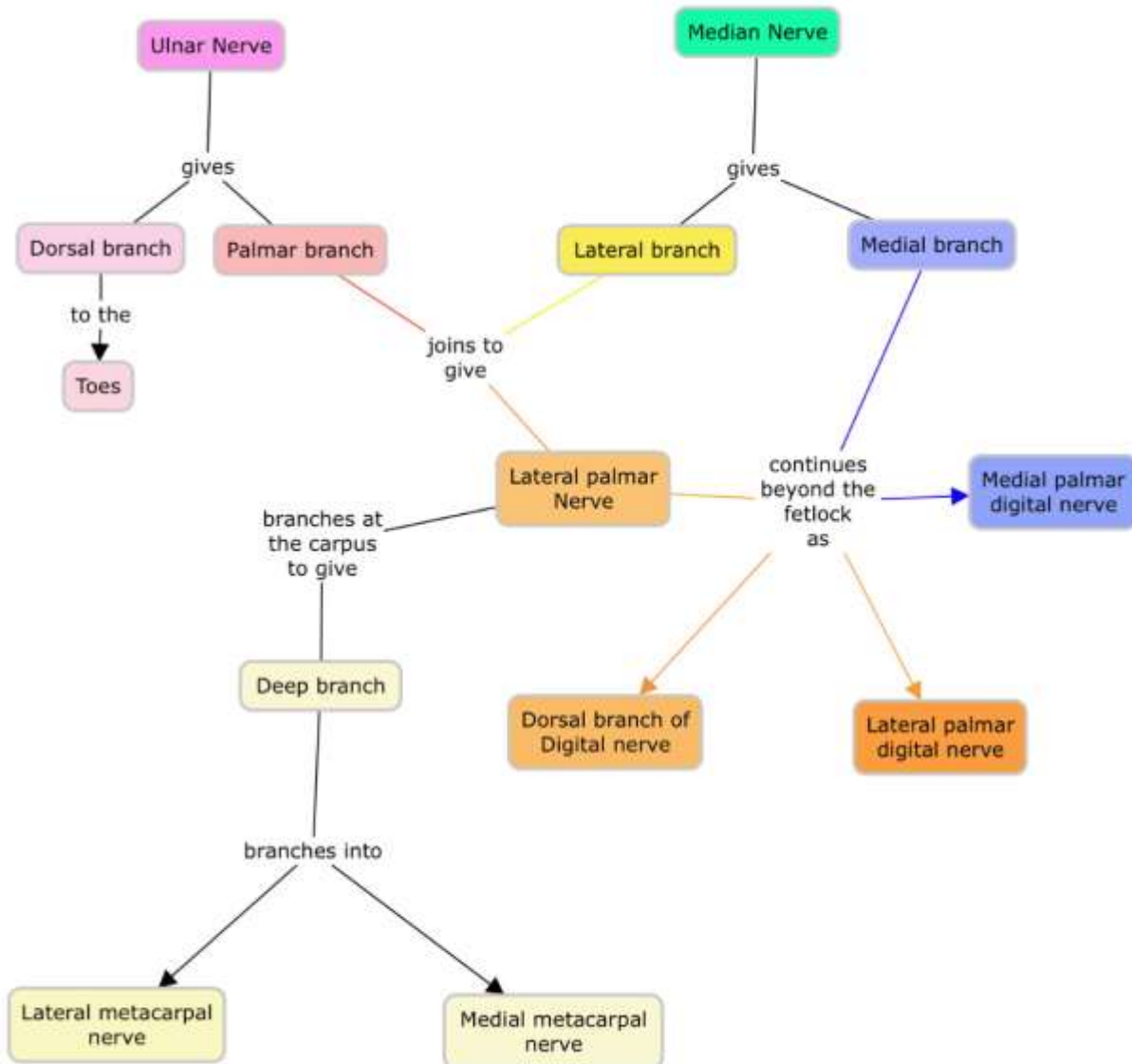
To the Manus

The Manus comprises of:

- Carpus
- Metacarpus
- Digits



A Layout of how the Nerves are Distributed in the Manus



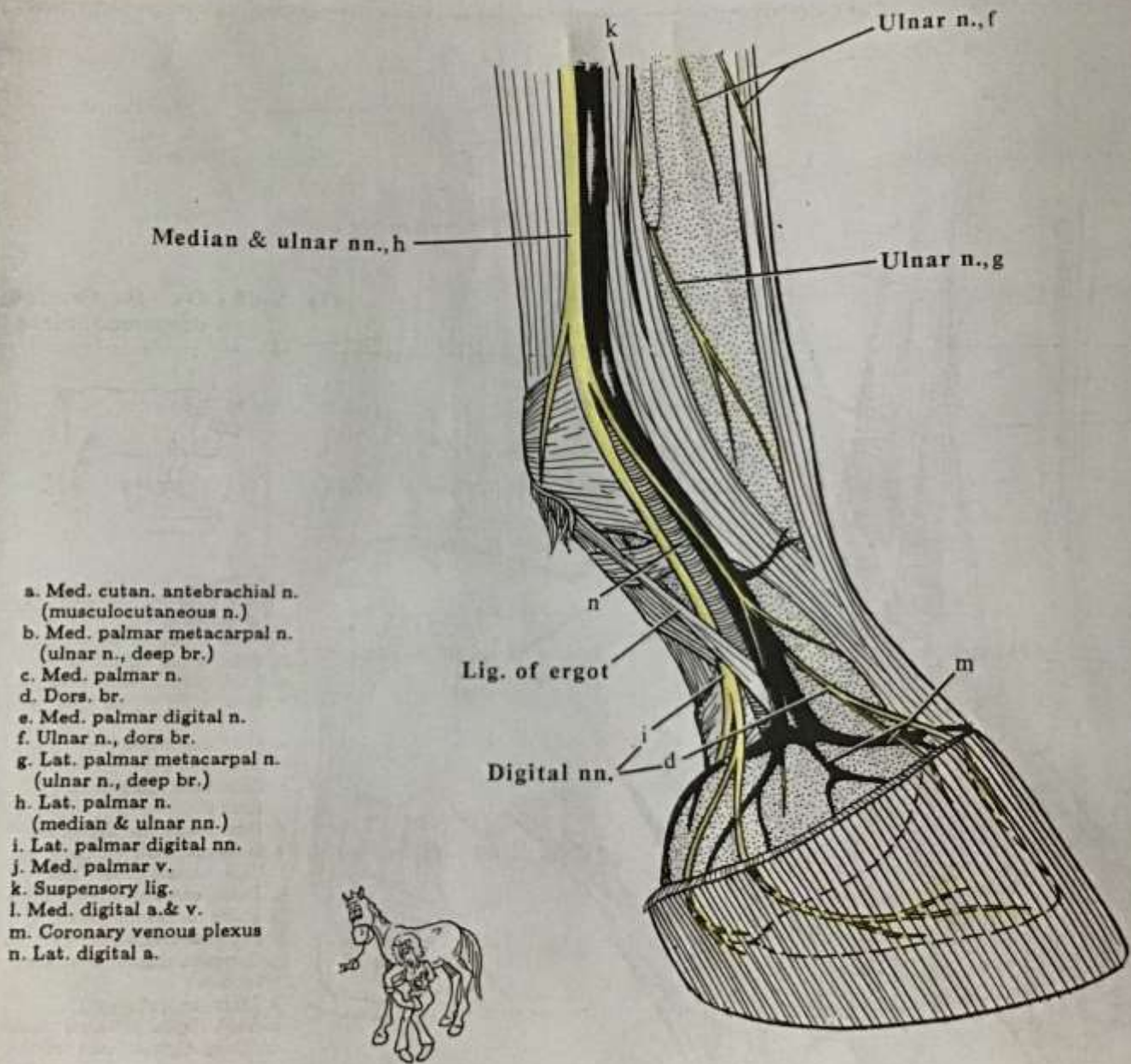


Fig. X-67 - Horse - Forefoot

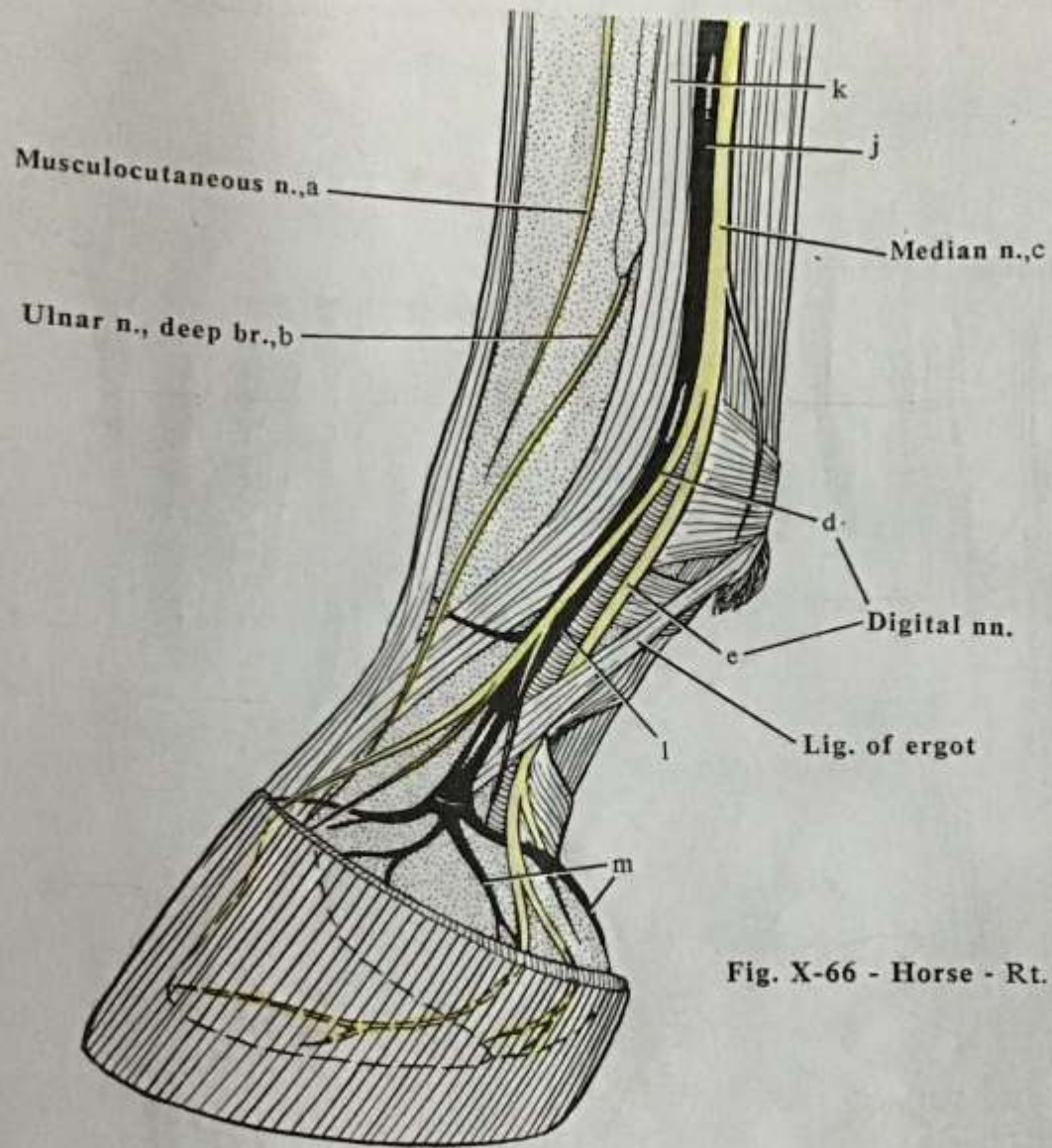
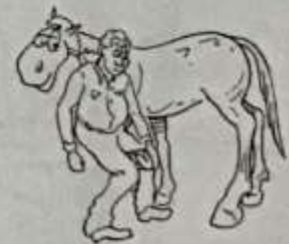

Fig. X-66 - Horse - Rt. forefoot - med. view



Nerve	Motor Innervation to...	Sensory Innervation to...
Ulnar <ul style="list-style-type: none"> • Dorsal br • Palmar br <ul style="list-style-type: none"> ○ Deep br ○ Superficial br <ul style="list-style-type: none"> ▪ Joins with median n. to form the lateral palmar n. 		Dorsolateral of the manus till the fetlock
Median <ul style="list-style-type: none"> • Medial br <ul style="list-style-type: none"> ○ Dorsal br ○ Medial palmar digital br • Lateral palmar <ul style="list-style-type: none"> ○ Deep br <ul style="list-style-type: none"> ▪ Medial & Lateral metacarpal 	<ul style="list-style-type: none"> • Splint bones & deep metacarpal structures 	<ul style="list-style-type: none"> • Medial aspect of metacarpus <ul style="list-style-type: none"> ○ Dorsum of digit and corium of hoof ○ Palmar aspect of digit, digital joints & cushion and corium of hoof