



Continuing Education Article #4  
Refereed Peer Review

# Cryptorchidism in Horses. Part II. Treatment\*

Auburn University  
Dwayne H. Rodgerson, DVM  
R. Reid Hanson, DVM

Cryptorchid stallions often display the physical and behavioral characteristics of normal stallions. To eliminate masculine characteristics, testes are routinely removed from entire and cryptorchid stallions. The numerous approaches for cryptorchidectomy that have been used in horses include the inguinal,<sup>1-7</sup> parainguinal,<sup>6,8-10</sup> modified parainguinal,<sup>11</sup> suprapubic paramedian,<sup>12-16</sup> and paralumbar flank<sup>8,17-19</sup> approaches; each has advantages and disadvantages. Abdominal testes also can be removed by laparoscopic techniques.

For removal of cryptorchid testes, horses are usually anesthetized and positioned in dorsal recumbency. Laparoscopic techniques and the flank approach for removing abdominal testes, however, can be performed with the patient standing.<sup>7,17,20-23</sup>

## PRESURGICAL CONSIDERATIONS

Special considerations should be instituted before cryptorchidectomy. Food should be withheld for 12 hours before surgery to decrease the amount of ingesta and gas in the gastrointestinal tract, making it easier to locate the abdominal testis and suture an incision in the abdominal wall.<sup>5,9,13,19</sup> Laparoscopic techniques require that food be withheld for 24 to 48 hours before surgery<sup>20,21,24</sup> to improve visualization of intraabdominal structures and to decrease the likelihood that a laparoscopic instrument will penetrate a viscus.<sup>20,21</sup>

The use of and rationale for antibiotic therapy in horses undergoing cryptorchidectomy vary among surgeons.<sup>17,23</sup> If used, antibiotics should be administered before surgery to ensure systemic concentrations during the procedure. Administration of broad-spectrum antibiotics should be continued after surgery if aseptic technique was disrupted during the procedure. Tetanus prophylaxis should be used when cryptorchidectomy is performed.

\*Part I of this two-part presentation appeared in the November 1997 (Vol. 19, No. 11) issue of *Compendium*.

## FOCAL POINT

- ★ Cryptorchidectomy can be performed through an inguinal, parainguinal, modified parainguinal, suprapubic paramedian, paralumbar flank, or laparoscopic approach.

## KEY FACTS

- If it is situated in the inguinal canal, the testis can be removed via a routine castration technique, p. 1373.
- An approach is considered to be noninvasive if it involves removing the testis either without entering the abdomen or entering the abdomen with only one or two fingers, p. 1373.
- The modified parainguinal approach to an abdominal testis does not disrupt the vaginal ring, and closure of the external sheath of the external abdominal oblique muscle provides secure closure of the abdomen, p. 1374.
- If laparoscopic cryptorchidectomy can be performed in a standing horse, general anesthesia is avoided and the vaginal ring is easily identified, p. 1376.

## APPROACHES ASSOCIATED WITH THE INGUINAL CANAL

Inguinal and abdominal testes are commonly removed via an inguinal, parainguinal, or modified parainguinal approach. These approaches, which enable visualization of the superficial inguinal ring and inguinal canal, differ according to where the abdomen is entered to retrieve the retained testis<sup>25-27</sup> (Figure 1). In unilateral cryptorchids, modified scrotal ablation can be used to visualize the inguinal canal.<sup>28</sup> If the location of the retained testis is unknown, the superficial inguinal ring and inguinal canal should be explored before the abdomen is entered.

For the inguinal and parainguinal approach, an 8- to 15-cm cutaneous incision is made directly over the superficial inguinal ring.<sup>1,3,4,6,7,29</sup> For the modified parainguinal approach, a 15-cm incision is made 2 cm medial and parallel to the medial crus of the superficial inguinal ring, centered along the cranial extent of the ring.<sup>11</sup> For cryptorchidectomy in unilateral cryptorchids, the cutaneous incision for the inguinal and parainguinal approach can be made through the scrotum.<sup>28</sup> Midline scrotal ablation involves removing the scrotal and retained testes through an elliptic incision over the scrotal testis.<sup>28</sup> The incision is retracted cranially to identify the superficial inguinal ring on the side of testicular retention.<sup>28</sup>

Once the cutaneous incision is made, the inguinal fascia is bluntly separated (with the surgeon's fingers) and the dissection is continued down to the superficial inguinal ring. Careful inspection of the inguinal canal facilitates identification of an inguinal retained testis. If the testis is in the inguinal canal, it is removed via routine castration.<sup>25,30</sup> If a testis is not identified in the canal, it can be located in the abdomen and removed via a noninvasive or invasive approach.<sup>1,4,27,31</sup>

An approach is considered to be noninvasive if the testis can be retrieved without entering the abdomen or by

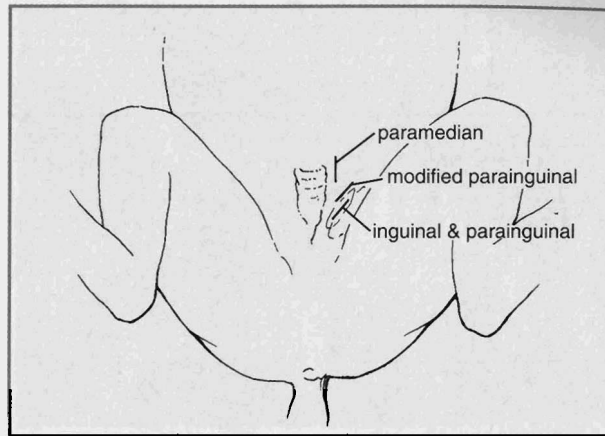


Figure 1A

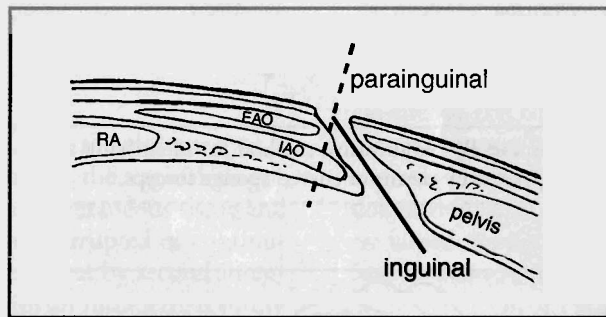


Figure 1B

**Figure 1—(A)** Cutaneous incisions used for the inguinal and parainguinal, modified parainguinal, and suprapubic paramedian approaches. **(B)** Cross-section of the inguinal canal, showing the positions of the abdominal incisions for the inguinal and parainguinal approaches (*EAO* = external abdominal oblique muscle, *IAO* = internal abdominal oblique muscle, *RA* = rectus abdominis muscle).

entering the abdomen with only one or two fingers.<sup>25</sup> An approach that requires insertion of a hand into the abdomen to retrieve the testis is considered to be invasive.<sup>25</sup>

## Locating and Everting the Vaginal Process

Using a noninvasive inguinal approach, the testis can be exteriorized through an incision in the vaginal process. A vaginal process that is everted in the inguinal canal can be easily identified and grasped with forceps. A vaginal process inverted into the abdomen can be everted into the inguinal canal by one of two methods.

In one method, the surgeon's four fingers are introduced through the superficial inguinal ring and into the inguinal canal. One of the fingers, usually the ring finger, passes through the vaginal ring and into the inverted vaginal process.<sup>1</sup> A 25-cm, curved sponge forceps (or another type of long-handled, blunt forceps) is inserted into the vaginal process beside the finger<sup>1,29,32,33</sup> (Figure 2). The

forceps is gently pushed against the inverted vaginal process, and a portion of the process is grasped in the jaws of the forceps.<sup>1</sup> The vaginal process is everted and identified by placing gentle traction on the forceps.

Another method of locating and everting an inverted vaginal process is to place traction on the fibers of the pars infravaginalis gubernaculi,<sup>34</sup> which is the extra-abdominal segment of the gubernaculum (the elongated scrotal ligament), or on the inguinal extension of the gubernaculum testis<sup>4,31</sup> (Figure 3). Careful dissection of tissue at the edge of the superficial inguinal ring allows identification of the pars infravaginalis gubernaculi, which is a white, fibrous band 0.5 to 2.0 cm wide.<sup>4</sup> The pars infravaginalis gubernaculi usually enters the superficial inguinal ring at the craniomedial or craniolateral aspect of the inguinal canal.<sup>4,25,31</sup> Once the pars infravaginalis gubernaculi is identified, moderate traction is placed on it to exteriorize the inverted vaginal process.<sup>4,31</sup>

When the vaginal process is exteriorized, it is incised longitudinally to expose the epididymis and the proper ligament of the testis. Moderate tension on the ligament, which connects the tail of the epididymis to the testis, pulls the testis through the vaginal ring. Especially in a mature horse, it may be necessary to dilate the ring to allow the testis to pass.<sup>1,31</sup>

### Exploring the Abdomen

If the vaginal process cannot be identified or if a previous attempt at castration has disrupted the anatomy of the inguinal canal, the surgeon can enter the abdomen and digitally explore the vaginal ring for the retained testis. The modified parainguinal approach is commonly used to explore the abdomen.<sup>11</sup> For a noninvasive modified parainguinal approach, a 4- to 6-cm incision is made in the external sheath of the external abdominal oblique (EAO) muscle 1 to 2 cm medial to the superficial inguinal ring and centered over the cranial aspect of the ring.<sup>11</sup>

By means of blunt dissection, the internal abdominal oblique (IAO) muscle, retroperitoneal fat, and peritoneum are penetrated, and the abdomen is explored with one or two fingers. Correct placement of the incision in the external sheath of the EAO muscle is important to allow digital examination of the vaginal ring. If the testis or epididymis cannot be located digitally, the incision in the sheath is enlarged and the surgeon's hand is introduced into the abdomen.

Using a noninvasive or invasive parainguinal approach, the abdomen is entered by bluntly separating the fibers of the IAO muscle (deep to the craniomedial border of the superficial inguinal ring) and penetrating the peri-

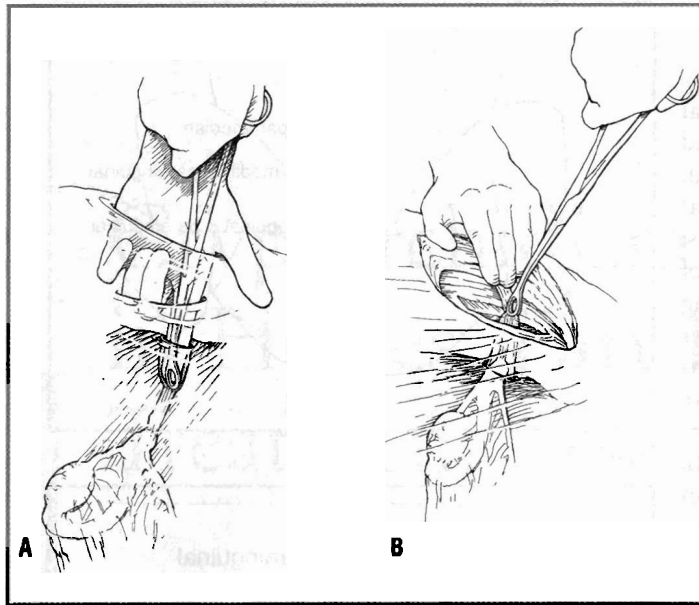


Figure 2—(A and B) Noninvasive method for identifying and everting the vaginal process by means of curved sponge forceps.

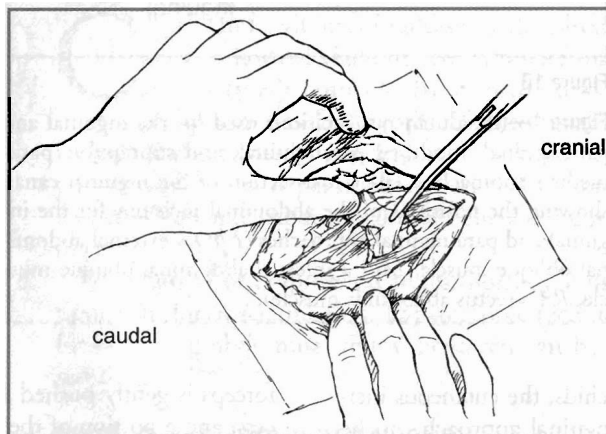


Figure 3—Noninvasive method for identifying the vaginal process by means of the inguinal extension of the gubernaculum.

toneum.<sup>5,6,8-11</sup> The abdomen is initially explored with one or two fingers; a hand is used if the testis cannot be identified via digital search. The parainguinal and modified parainguinal approaches avoid disruption of the vaginal ring.

The abdomen can be entered directly through the inguinal canal using an invasive inguinal approach.<sup>1-7</sup> The hand is passed through the inguinal canal, and the abdomen is entered by tearing the vaginal ring or by bluntly penetrating the peritoneum near the vaginal ring. The invasive inguinal approach is associated with a high incidence of eventration.<sup>5,6,25,27</sup>

### Finding and Exteriorizing the Testis

An abdominal testis is usually found near the vaginal ring. Generally, only moderate traction is required to exteriorize the testis from the abdomen.<sup>8,11,15</sup> The incision into the abdomen should initially be large enough to accommodate one or two fingers, which are introduced into the abdomen to grasp and exteriorize the epididymis or testis. If the testis

or epididymis cannot be located by digital search, the abdominal incision is enlarged and the hand is introduced into the abdomen.

If the testis is still not readily located, the ductus deferens, in the genital fold of the bladder, is identified and traced from the bladder toward the epididymis and testis.<sup>7,8,14,26</sup> The mesorchium and associated testicular vessels, which extend from the region caudal to the ipsilateral kidney, can also be traced to search for an abdominal testis.<sup>5,26</sup> Identifying and tracing the testicular vessels to the testis, however, is more difficult than



identifying and tracing the ductus deferens.

After the testis is located and extracted from the abdomen or inguinal canal, the spermatic cord is crushed and severed with an emasculator. The cord can also be ligated to ensure hemostasis. The proximal portion of the spermatic cord is inspected for hemorrhage and, if not hemorrhaging, is released back into the inguinal canal or abdomen.

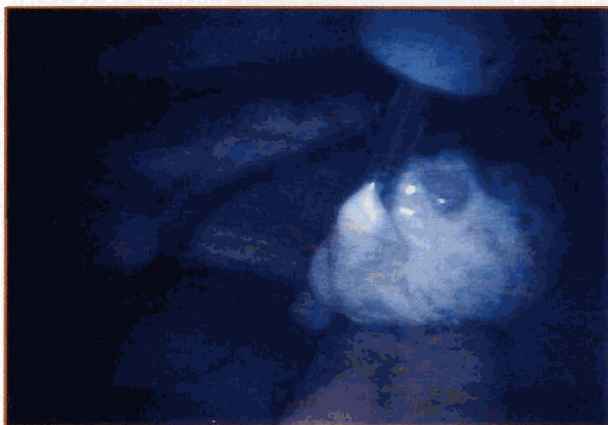


Figure 4—Laparoscopic identification of an abdominally retained testis.

### Closing the Abdomen and Preventing Eventration

If the testis was exteriorized from the abdomen via a noninvasive inguinal approach and the vaginal ring is not wider than two fingers, the subcutaneous tissue and skin are closed separately (with interrupted or continuous sutures) or left unapposed to heal by second intention. The skin can be closed with an intradermal suture pattern so that the sutures do not require removal.

If the vaginal ring or surrounding peritoneum is disrupted to the extent that the tips of two or more fingers can be easily inserted into the vaginal ring, the superficial inguinal ring should be closed to prevent eventration through the vaginal ring.<sup>1,7,10,17,25,31,35</sup> In closing the superficial inguinal ring, caution is necessary to avoid incarcerating a segment of intestine or mesentery in the closure. A hernia needle helps in avoiding intestinal incarceration while suturing the superficial inguinal ring.<sup>7,23</sup> Occasionally, the incision in the vaginal process can be closed to help prevent eventration before closure of the superficial inguinal ring.<sup>8</sup> After the ring is closed, the subcutaneous tissue and skin are closed separately (with interrupted or continuous sutures) or the incision is left unapposed to heal by second intention.

An alternative method of preventing eventration is to pack the inguinal canal for 24 to 48 hours with sterile gauze or a sterile towel.<sup>7,25,27,29,32,35</sup> Caution is necessary to ensure that the packing does not protrude through the vaginal ring and into the abdomen. Packing that protrudes through the ring prevents it from contracting, which could result in eventration after the packing is removed.<sup>25</sup> The intestine or omentum may adhere to the packing if it protrudes through the vaginal ring and into the abdomen. Primary closure of the skin helps secure the packing against the superficial inguinal ring.<sup>29</sup> Preventing eventration by suturing the superficial

inguinal ring is believed to be a better method than packing the inguinal canal.

If the abdomen was entered via a modified parainguinal approach, the external sheath of the EAO muscle is closed with interrupted or continuous sutures.<sup>11</sup> The subcutaneous tissue and skin are closed separately with interrupted or continuous sutures, or the incision is left unapposed to heal by second intention. This approach does not disrupt the vaginal ring, and closure of the external

sheath of the EAO muscle is secure and easier than closure of the superficial inguinal ring.<sup>11</sup> In the parainguinal approach, the IAO muscle, subcutaneous tissue, and skin are closed separately.<sup>31</sup> If a midline scrotal ablation technique was used, the subcutaneous tissue and skin are closed separately or the incision is left unapposed to heal by second intention.<sup>28</sup>

### Managing Recovering Patients

Horses that have undergone cryptorchidectomy should be restricted to clean stalls for 24 to 48 hours after surgery. Horses that have had an inguinal retained testis or an abdominal testis removed via noninvasive methods are treated like horses that have undergone routine castration. These patients should be hand-walked daily for at least 15 to 30 minutes or turned out into a small, dry paddock. Unlimited exercise (except for cantering, galloping, or jumping) is allowed. The patient can begin to return to unrestricted exercise at 10 to 14 days after surgery. If the abdomen was entered by an invasive method, 3 to 4 weeks of limited exercise might be necessary before unrestricted exercise is resumed.

### LAPAROSCOPIC CRYPTORCHIDECTOMY

Laparoscopy has been used to identify and remove abdominally retained testes<sup>20-22,36</sup> (Figure 4). The technique can be performed with the horse standing in stocks<sup>20-22,36</sup> or anesthetized and positioned in dorsal recumbency.<sup>21,36</sup> Regardless of the positioning, the abdominal cavity must be insufflated with gas (carbon dioxide, nitrous oxide, or helium) to 10 to 25 mm Hg.<sup>20-22,36,37</sup>

### Techniques in Standing Horses

When laparoscopic cryptorchidectomy is performed

in a standing horse, general anesthesia is avoided and the vaginal ring is easily identified. Horses are sedated with intravenous xylazine (0.5 mg/kg) or detomidine (0.02 to 0.03 mg/kg) in combination with butorphanol (0.02 to 0.05 mg/kg). The paralumbar fossa on the side of testicular retention is prepared for aseptic surgery and draped. If the location of the testis is unknown or if the horse is a bilateral cryptorchid, both paralumbar fossae are prepared and draped. The paralumbar fossa is desensitized (by regional anesthesia or direct infiltration of the region with local anesthesia) to allow placement of portals for insertion of the laparoscope and instruments.<sup>20-22,36</sup>

The abdominal cavity is insufflated with a Verres-type needle inserted high in the paralumbar fossa<sup>36</sup> or a teat cannula inserted ventrally (as if for abdominocentesis). The advantage of insufflating the abdomen with a teat cannula through the ventral abdomen is that peritoneal fluid obtained through the cannula demonstrates that the abdominal cavity has been entered. If the needle is inadvertently placed retroperitoneally (which is easy to do if the abdomen is insufflated through the paralumbar fossa), the retroperitoneal space will be insufflated rather than the peritoneal cavity. To avoid this complication, the trocar-cannula can be inserted through the paralumbar fossa before insufflation of the abdominal cavity.<sup>20,21,38</sup>

A 15-mm skin incision is made at the dorsal border of the IAO muscle, and the laparoscopic trocar-cannula is introduced into the abdominal cavity in a caudal direction (Figure 5). The trocar is replaced by the laparoscope, and the caudal portion of the abdomen is examined to identify the retained testis. The vaginal ring is easily located just cranial to the brim of the pelvis; an abdominal testis is usually visible hanging adjacent to the vaginal ring or at the end of the mesorchium.<sup>20,21,24</sup> If the horse is bilaterally cryptorchid, a scope portal through the opposite paralumbar fossa is usually necessary. The opposite vaginal ring, however, can be viewed by passing the laparoscope beneath the distal end of the small colon or through a rent created in the mesocolon.<sup>36</sup>

Once the testis has been identified, a second incision

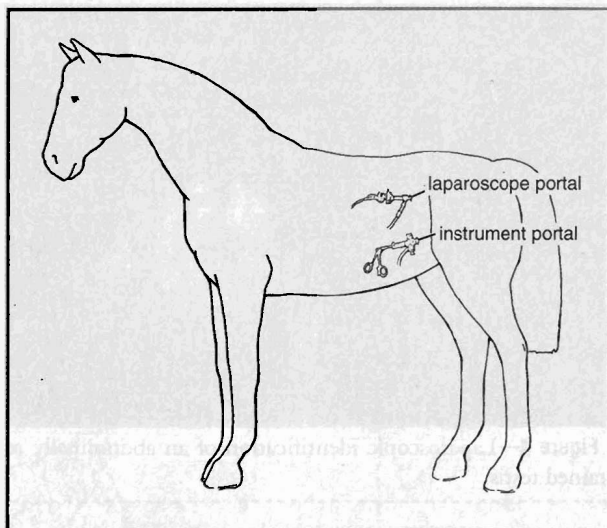


Figure 5—The locations of the laparoscope and instrument portals through the paralumbar fossa in a standing horse.

is made in the flank 10 to 15 cm caudoventral to the laparoscope portal (Figure 5). Long-handled forceps are inserted into the abdominal cavity, and the testis is grasped. It can be exteriorized through the instrument portal and then removed via an emasculator,<sup>20,21</sup> or the spermatic cord can be ligated and transected in the abdomen.<sup>22,36</sup> To facilitate exteriorizing the testis before removal, the testis or mesorchium is anesthetized with a local agent; a 20- to 30-cm, 18-gauge needle is passed through the paralumbar fossa and directed into the

testis or mesorchium. The instrument portal is enlarged, and the testis is exteriorized through it. The testis is removed with emasculators, and the spermatic cord is returned to the abdomen.

After the testis has been removed, the abdomen is deflated through a laparoscopic cannula. The superficial abdominal fascia and skin at the portals are closed separately.<sup>21</sup> If the horse is a bilateral cryptorchid, a second laparoscope and instrument portal is made through the opposite paralumbar fossa to remove the other testis.

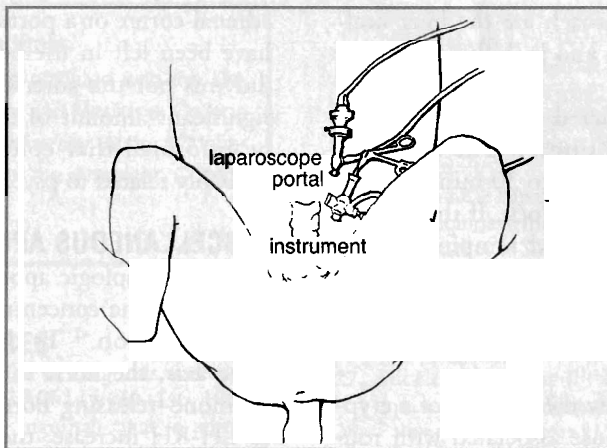
Recent reports describe ligating and transecting the spermatic cord in the abdomen and then exteriorizing the testes through the instrument portal.<sup>22,36</sup> In this technique, two instrument portals are necessary to ligate the testicular vessels. Epidural anesthesia was used to desensitize the caudal end of the abdomen instead of directly injecting the testis or mesorchium with a local anesthetic.<sup>22,36</sup>

### Techniques in Anesthetized Horses

To remove an abdominal testis from an anesthetized horse via a laparoscope, the patient is positioned in dorsal recumbency<sup>21,36</sup> (Figure 6). The caudal portion of the abdomen is clipped and prepared for aseptic surgery. A 15-mm cutaneous incision is made 15 to 20 cm cranial to the superficial inguinal ring and 10 cm from the midline<sup>21</sup> (Figure 6). A Verres-type needle or teat cannula is inserted into the abdomen through the incision, and the abdomen is insufflated. The laparoscopic trocar-cannula then is introduced through the skin incision and rectus abdominis (RA) muscle and into the abdominal cavity. The trocar is replaced with the laparoscope, and the

surgery table is tilted cranially approximately 30° (Trendelenburg's position) so that the abdominal viscera are displaced cranially to better expose the vaginal ring.

The instrument portal is made after the testis has been identified, and a 15-mm skin incision is made 4 cm cranial and axial to the ipsilateral superficial inguinal ring (Figure 6). The testis is grasped with laparoscopic forceps, and the instrument portal is enlarged to exteriorize the testis. The spermatic cord is crushed and severed, and the proximal end is returned to the



**Figure 6**—The locations of the laparoscope and instrument portals for a cryptorchidectomy procedure in an anesthetized horse.

abdomen. The cord can also be ligated and transected in the abdominal cavity, but a second instrument portal is required.<sup>37</sup> The abdomen is deflated, and the external fascia of the RA muscle, the subcutaneous tissue, and the skin at the portals are closed separately.<sup>21</sup> In cases of bilateral cryptorchidism, the contralateral testis is removed by the same technique.

The scrotal testis of a unilateral cryptorchid is usually removed separately by routine castration. Recent reports describe pulling a scrotal or inguinal testis into the abdominal cavity, by enlarging the vaginal ring, for removal through a laparoscope portal.<sup>36,37</sup> Inguinal or scrotal testes can be destroyed by a laparoscopic technique. The testicular vessels and vas deferens of such testes can be cauterized or ligated in the abdomen, causing the testis to undergo avascular necrosis in the scrotum or inguinal canal.<sup>37</sup>

Because laparoscopic cryptorchidectomy can be accomplished through small incisions, horses can be returned to exercise shortly after the procedure is performed.<sup>21</sup> The patient should be confined to a stall for the first 24 hours after surgery. Light exercise is then allowed for 7 to 10 days before the horse is returned to unrestricted exercise.

### SUPRAPUBIC PARAMEDIAN APPROACH

The suprapubic paramedian approach is used occasionally when the testis has been definitively determined to be in the abdomen before surgery or after the inguinal canal has been surgically explored (through a scrotal incision or an incision directly over the superficial inguinal ring).<sup>12-16</sup> To remove a testis retained in the abdomen via a suprapubic paramedian approach, an 8- to 15-cm incision is

made 7 to 10 cm lateral and parallel to the ventral midline on the affected side.<sup>12-16</sup> The incision is continued through the external sheath, RA muscle fibers, internal sheath, retroperitoneal fat, and peritoneum. The abdomen is explored as described for the inguinal approach.

After the testis is removed, the outer RA sheath, subcutaneous tissue, and skin are closed separately with an interrupted or continuous suture pattern. The patient is restricted to a clean stall for the first 24 to 48 hours. The horse is then hand-walked

daily for at least 15 to 30 minutes or is turned out into a small, dry paddock. Unrestricted exercise can be started after 3 to 4 weeks.

The advantages of the suprapubic paramedian approach are that (1) bilaterally retained testes often can be exteriorized and removed through one abdominal incision (although the contralateral testis may be difficult to exteriorize) and (2) large cystic or neoplastic testes can be removed.<sup>14,25</sup> A disadvantage of this approach is that a separate inguinal or scrotal incision is necessary to explore the inguinal canal if the location of the testis is unknown.<sup>14-16</sup>

### PARALUMBAR FLANK APPROACH

Although not commonly used to remove abdominal-retained testes, the incisional flank approach can be performed with the horse standing or anesthetized in lateral recumbency.<sup>8,17-19,25,26</sup> Because an inguinal retained testis cannot be removed using a flank approach, the surgeon must be confident that the retained testis is located in the abdomen.<sup>1,25,26</sup> The procedure allows the removal of bilateral cryptorchid testes through one incision, but the contralateral testis must be excised blindly with a chain écraseur.<sup>18</sup>

If surgery is performed with the patient standing, the paralumbar fossa must be anesthetized with a local agent. A 10- to 15-cm vertical incision is made in the middle flank region, and the peritoneum is exposed by a muscle-splitting grid technique. The peritoneum is perforated, and the hand is introduced into the abdomen. After the testis is removed, the IAO muscle and peritoneum, EAO muscle, and skin are closed separately using interrupted or continuous sutures. The major

disadvantages of the flank approach are the long healing period, incisional scarring, and inability to remove an inguinally retained testis.

The patient should be restricted to a clean stall for the first 24 to 48 hours after surgery. The horse can then be hand-walked for at least 15 to 30 minutes daily or turned out into a small, dry paddock. If the horse is turned out, cantering, galloping, and jumping are not permitted. Unrestricted exercise can be resumed after 3 weeks.<sup>17</sup>

## COMPLICATIONS

The complications that follow the removal of a cryptorchid testis are similar to those associated with routine castration.<sup>39</sup> Intraabdominal hemorrhage from the spermatic vessels is a serious and possibly fatal complication that may be undetected at the time of surgery.<sup>23</sup> The crushed or ligated end of the cord thus should be inspected closely for hemorrhage before the cord is returned to the abdomen, and the patient should be confined to a stall for the first 24 hours after surgery.<sup>23,25</sup>

Clinical signs that are associated with blood loss include tachycardia, pale mucous membranes, weakness or ataxia, weak and thready pulse, and poor jugular distention.<sup>39</sup> Hemorrhage should be stopped, and initial medical therapy should be aimed at replacing the lost blood volume by administering intravenous fluids and whole blood.

Eventration is an emergency that requires immediate attention to minimize contamination and strangulation of intestine.<sup>39</sup> Prolapse of the small intestine through the inguinal canal has been reported after routine castration<sup>39</sup> and cryptorchidectomy performed through an inguinal approach.<sup>5,6,25</sup> Noninvasive removal of abdominal testes is associated with a lower incidence of eventration.<sup>4,27</sup> If the vaginal ring is disrupted, the superficial inguinal ring should be sutured or the inguinal canal packed.<sup>7,23</sup> The superficial ring must be closed carefully to prevent inadvertent incarceration of intestine in the closure.

Proper aseptic techniques should be used throughout cryptorchidectomy procedures; improper techniques can result in septic peritonitis. Administering perioperative antibiotics can help to prevent this condition.<sup>6</sup> Intraabdominal adhesions after abdominal procedures can be avoided by adherence to proper aseptic technique and prevention of excessive trauma to the surfaces of the gastrointestinal serosa.

Castrated horses may continue to display masculine behavior after cryptorchidectomy.<sup>25</sup> Stallionlike sexual interest toward mares is reportedly displayed by 20% to 30% of castrated horses.<sup>40</sup> Such masculine behavior is often attributed to production of testosterone from the

adrenal cortex or a portion of the epididymis that may have been left in the horse; however, neither the epididymis nor the adrenal cortex produces or secretes a significant amount of testosterone.<sup>25,41</sup> Owners should be informed that continued masculine behavior is probably related to psychologic causes.<sup>25</sup>

## MISCELLANEOUS APPROACHES IN STALLIONS

An immunologic approach to castration can be used to decrease the concentration of testosterone in a cryptorchid stallion.<sup>42</sup> To disrupt the reproductive–endocrine axis, the horse is immunized against luteinizing hormone–releasing hormone (LH-RH). As antibodies to LH-RH increase, the concentration of testosterone decreases to a level similar to that of castrated horses.<sup>42</sup> The primary immunization is followed by immunizations at 2, 4, and 8 weeks to produce and maintain a decrease in serum testosterone concentration. Because the concentration eventually increases as the antibody titers to LH-RH decrease, a fourth immunization is administered 7 months after the third.<sup>42</sup>

Orchiopexy, induction of testicular descent through hormonal therapy, and implantation of a prosthesis into the scrotum are not recommended or effective methods of treating horses with cryptorchidism.<sup>26,34,43</sup> Orchiopexy and induction of testicular descent by hormonal therapy are unethical in light of the possible heritability of cryptorchidism.<sup>26,43</sup>

Such induction of testicular descent is likely to be unsuccessful in a horse because rapid constriction of the vaginal ring during the first 2 weeks after parturition impedes the descent of the testes<sup>8,44</sup> and because the gubernaculum is probably inactive or unresponsive to hormonal therapy after birth.<sup>34,45</sup> Implantation of a testicular prosthesis into the scrotum of a cryptorchid horse is an unethical procedure that is performed to mask cryptorchidism.

## CONCLUSION

Surgical removal of the testes helps to diminish masculine behavior in cryptorchid stallions. Cryptorchidectomy can be performed through various approaches. If the location of the testis is unknown, the inguinal region should be searched carefully. The noninvasive inguinal and modified parainguinal approaches are commonly used. Laparoscopic removal of abdominal testes is increasingly popular.

## ACKNOWLEDGMENT

The authors thank Lisa Makarchuk of Biomedical Communications, Auburn University, for providing the figures.



### About the Authors

Drs. Rodgers and Hanson are affiliated with the Department of Large Animal Surgery and Medicine, College of Veterinary Medicine, Auburn University, Auburn, Alabama. Dr. Hanson is a Diplomate of the American College of Veterinary Surgeons.

### REFERENCES

- Adams OR: An improved method of diagnosis and castration of the cryptorchid horse. *JAVMA* 145:439-446, 1964.
- Wright JG: The surgery of the inguinal canal in animals. *Vet Rec* 75:1352-1363, 1963.
- Merriam JG: An inguinal approach to equine cryptorchidectomy. *VM SAC* 67:187-191, 1972.
- Valdez H, Taylor TS, McLaughlin SA, et al: Abdominal cryptorchidectomy in the horse, using inguinal extension of the gubernaculum testis. *JAVMA* 174:1110-1112, 1979.
- Hobday FTG: The castration of cryptorchid horses, in Hobday FTG (ed): *The Castration of Cryptorchid Horses and the Ovariectomy of Troublesome Mares*. New York, William R. Jenkins, 1903, pp 17-64.
- O'Connor JJ: Operations—Castration of cryptorchids, in O'Connor JJ (ed): *Dollar's Veterinary Surgery*, ed 2. London, Baillière, Tindall & Cox, 1930, pp 322-336.
- Vaughan JT: Surgery of the testes, in Walker DF, Vaughan JT (eds): *Bovine and Equine Urogenital Surgery*. Philadelphia, Lea & Febiger, 1980, pp 156-163.
- Arthur GH: The surgery of the equine cryptorchid. *Vet Rec* 73:385-389, 1961.
- Cox JE: Cryptorchid castration, in McKinnon AO, Voss JL (eds): *Equine Reproduction*. Philadelphia, Lea & Febiger, 1993, pp 915-920.
- Bishop MWH, David JSE, Messervy A: Some observations on cryptorchidism in the horse. *Vet Rec* 76:1041-1048, 1964.
- Wilson DG, Reinertson EL: A modified parainguinal approach for cryptorchidectomy in horses. An evaluation in 107 horses. *Vet Surg* 16:1-4, 1987.
- Cox JE: A surgical approach to the cryptorchid horse. *In Pract* 10:11-16, 1988.
- Cox JE, Neal PA, Edwards GB: Suprapubic paramedian laparotomy for equine abdominal cryptorchidism. *JAVMA* 173:680, 1978.
- Cox JE, Edwards GB, Neal PA: Suprapubic paramedian laparotomy for equine abdominal cryptorchidism. *Vet Rec* 97:428-432, 1975.
- Lowe JE, Higginbotham R: Castration of abdominal cryptorchid horses by a paramedian laparotomy approach. *Cornell Vet* 59:121-126, 1969.
- Wright JG: Laparo-orchidectomy in the horse with abdominal cryptorchidism. *Vet Rec* 72:57-60, 1960.
- Collier MA: Equine cryptorchidectomy: Surgical considerations and approaches. *Mod Vet Pract* 61:511-515, 1980.
- Ross MW: Standing abdominal surgery. *Vet Clin North Am Equine Pract* 7:627-629, 1991.
- Swift PN: Castration of a stallion with bilateral abdominal cryptorchidism by flank laparotomy. *Aust Vet J* 48:472-473, 1972.
- Fischer AT: Standing laparoscopic surgery. *Vet Clin North Am Equine Pract* 7:641-647, 1991.
- Fischer AT, Vachon AM: Laparoscopic cryptorchidectomy in horses. *JAVMA* 201:1705-1708, 1992.
- Hendrickson DA, Wilson DG: Laparoscopic cryptorchidectomy in standing horses. *Proc AAEP* 42:184-185, 1996.
- Vaughan JT: Surgery of the male equine reproductive system, in Jennings PB (ed): *The Practice of Large Animal Surgery*. Philadelphia, WB Saunders Co, 1984, pp 1083-1108.
- Wilson DG: Laparoscopy as an aid in the surgical management of the equine hemicastrate. *Proc AAEP* 35:347-353, 1990.
- Schumacher J: Surgical disorders of the testicle and associated structures, in Auer JA (ed): *Equine Surgery*. Philadelphia, WB Saunders Co, 1992, pp 674-703.
- Trotter GW: Normal and cryptorchid castration. *Vet Clin North Am Equine Pract* 4:493-513, 1988.
- Stickle RL, Fessler JF: Retrospective study of 350 cases of equine cryptorchidism. *JAVMA* 172:343-346, 1978.
- Palmer SE, Passmore JL: Midline scrotal ablation technique for unilateral cryptorchid castration in horses. *JAVMA* 190:283-285, 1987.
- Turner AS, McIlwraith CW: Cryptorchidectomy by non-invasive inguinal approach, in Turner SA, McIlwraith CW (eds): *Techniques in Large Animal Surgery*, ed 2. Philadelphia, Lea & Febiger, 1989, pp 185-191.
- Varner DD, Schumacher J, Blanchard TL, et al: Castration techniques, in Varner DD, Schumacher J, Blanchard TL, Johnson L (eds): *Diseases and Management of Breeding Stallions*. Goleta, CA, American Veterinary Publications, 1991, pp 143-158.
- Arighi M, Horney JD, Bosu WTK: Noninvasive inguinal approach for cryptorchidectomy in thirty-eight stallions. *Can Vet J* 29:346-349, 1988.
- Genetzky RM, Shira MJ, Schneider EJ, et al: Equine cryptorchidism: Pathogenesis, diagnosis, and treatment. *Compend Contin Educ Pract Vet* 6(10):S577-S582, 1984.
- Moore JN, Johnson JH, Tritscher LC, et al: Equine cryptorchidism: Pre-surgical considerations and surgical management. *Vet Surg* 7:43-47, 1978.
- Smith JA: The development and descent of the testis in the horse. *Vet Annu* 15:156-161, 1975.
- Varner DD, Schumacher J, Blanchard TL, et al: Diseases of the testes, in Varner DD, Schumacher J, Blanchard TL, Johnson L (eds): *Diseases and Management of Breeding Stallions*. Goleta, CA, American Veterinary Publications, 1991, pp 193-232.
- Hendrickson DA, Wilson DG: Laparoscopic and thoracoscopic surgery in the horse. *Vet Clin North Am Equine Pract* 12:235-259, 1996.
- Wilson DG, Hendrickson DA, Cooley AJ, et al: Laparoscopic methods for castration of equids. *JAVMA* 209:112-114, 1996.
- Witherspoon DM, Kraemer DC, Seager SWJ: Laparoscopy in the horse, in Harrison RM, Wildt DE (eds): *Animal Laparoscopy*. Baltimore, Williams & Wilkins, 1980, pp 157-167.
- Hunt RJ: Management of complications associated with equine castration. *Compend Contin Educ Pract Vet* 13(12):1835-1843, 1991.
- Line SW, Hart BL, Sanders L: Effect of prepubertal versus postpubertal castration on sexual and aggressive behavior in male horses. *JAVMA* 186:249-251, 1985.
- Crowe CW, Gardner RE, Humburg JM, et al: Plasma testosterone and behavioral characteristics in geldings with intact epididymides. *J Equine Med Surg* 1:387-390, 1977.
- Schanbacher BD, Pratt BR: Response of a cryptorchid stallion to vaccination against luteinising hormone releasing

(continues on page 1395)



**Cryptorchidism** (continued from page 1379)

- hormone. *Vet Rec* 116:74-75, 1985.
43. Hinrichs K, Gentile DG, Hurtgen JP, et al: Complications from a testicular prosthesis in a stallion. *JAVMA* 186:390-391, 1985.
  44. Bergin WC, Gier HT, Marion GB, et al: A developmental concept of equine cryptorchidism. *Biol Reprod* 3:82-92, 1970.
  45. Blanchard TL, Schumacher J, Taylor TS, et al: Detecting unilateral and bilateral cryptorchidism in large animals. *Vet Med* 85:395-403, 1990.