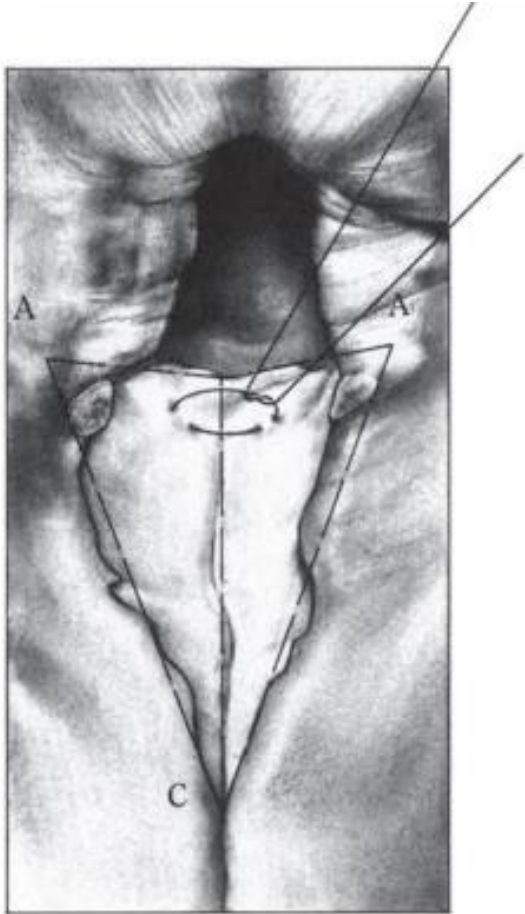


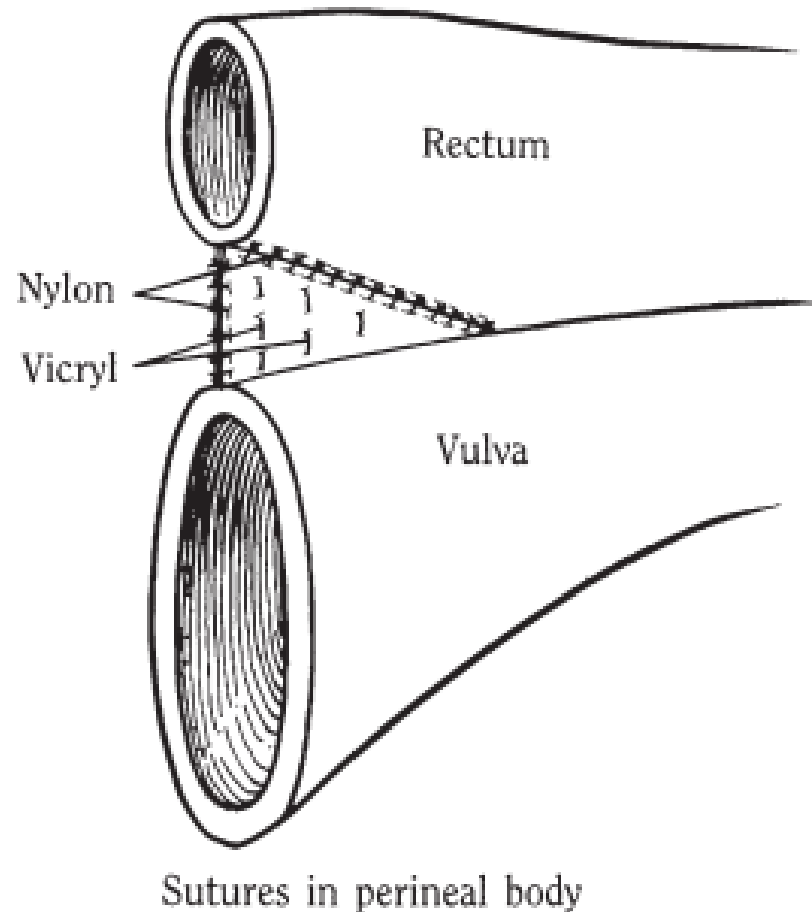


STAGE 2

- Surgical preparation and anaesthesia for the second stage of the procedure are like those for the first stage.
- Examine the retrovestibular shelf for healing, and if a small, granulating fistula remains, delay the second stage until it is healed. When a large fistula remains, the shelf is converted to a third-degree perineal laceration, and the first stage is repeated.
- Local infiltration of lidocaine can be used, instead of epidural anaesthesia.
- Remove the newly formed epithelialized tissue to obtain fresh surfaces for reconstruction and healing of the perineal body.



- Make an incision that starts at the cranial margin of the perineal body, extends peripherally along the scar tissue margin and ends at the dorsal commissure of the vulva, forming two sides of a triangle. Make an incision on the opposite side, and remove a superficial layer of epithelium, to create two raw, triangular surfaces. Undermine the skin of the perineum and reflect laterally to permit subsequent closure of the skin without undue tension.



- Begin closure of the deep layers of the perineal body cranially with simple interrupted sutures. Complete this closure with simple interrupted sutures placed within the epithelial edges of the rectum.
- Place the sutures alternately until reconstruction of the perineal body is completed.
- Do not attempt to locate and to suture the ends of the anal sphincter muscle because it is usually surrounded by scar tissue.
- Remove the dorsal portion of the vulvar lips as in Caslick's operation for pneumovagina.
- Close the skin of the perineum and lips of the vulva with interrupted sutures.

Reference

- Hendrickson D. Techniques in Large Animal Surgery. 3rd ed. Ames: Blackwell Publishing