

Teat Laceration Repair in Cattle

Sylvain Nichols, DMV, MS

*Department of Clinical Sciences, Université de Montréal, Faculté de Médecine Vétérinaire,
3200 Rue Sicotte, St-Hyacinthe, Québec, Canada, J2S 2M2*

Teat injuries are common in dairy cattle, and, compared with other frequently occurring diseases, these injuries often result in premature culling of affected cows [1,2]. Teat injuries can be divided into two categories (external or internal injuries). All the different types of injuries/diseases, diagnostic approaches, and therapies have been described in a previous text [3]. This chapter focuses only on teat lacerations (external injury).

Teat lacerations are viewed as catastrophic injuries for the survival of a cow within the herd. Many clients do not realize that when treated appropriately and promptly, it is possible to repair the teat and keep the animal in full production. For a bovine practice, it is a valuable service to offer to the client. Teat lacerations can be challenging to repair, but with the appropriate knowledge and material, a practitioner can be very successful at it.

Not all lacerations are the same. Different prognoses are associated with different types of lacerations. A classification of the laceration with regard to the duration, the conformation, the localization, and the thickness are presented. Preoperative preparation and surgical principles are discussed. Finally, postoperative care and possible complications are presented.

Classification

Teat lacerations are classified according to the duration from time of trauma, the localization and conformation of the laceration, and the thickness of the lesion (full or partial thickness). Different prognoses are associated with different classifications. It is important to understand the differences between each situation to be able to inform the client accordingly.

Duration

Teat lacerations are categorized as acute or chronic (more than 12 hours old). Surgical intervention on the teat is best performed during the first

E-mail address: sylvain.nichols@umontreal.ca

12 hours after the injury [3,4]. Later, swelling of the teat can be too severe to permit adequate reconstruction of the tissue. These injuries benefit from medical therapy (hydrotherapy and a nonsteroidal anti-inflammatory drug) (NSAID) before attempting primary closure of the defect (delayed first intention healing) (Fig. 1). However, with complex lacerations (inverted “Y” or “U”), it is recommended to try primary closure even if the laceration is older than 12 hours. The repair may partially dehisce, but the portion that heals will facilitate the surgical revision performed later in the healing process.

Localization and conformation

Teat lacerations are classified as simple or complex (inverted “Y” or “U”) (Fig. 2), longitudinal or transverse, and proximal or distal. The orientation of the blood supply of the teat is longitudinal. A transverse laceration (Fig. 3) results in more damage to the blood supply resulting in more edema, avascular necrosis, and dehiscence postoperatively compared with a longitudinal laceration. The more circumference is involved, the worse is the prognosis. Distal injuries involving the streak canal are also regarded as having a poor prognosis. Reconstruction of the streak canal is difficult and can cause partial or complete milk flow obstruction. Injury to the distal end of the teat compromises the defense mechanisms of the quarter against mastitis making the animal at higher risk for clinical or subclinical mastitis. Finally, distal injuries may lead to avascular necrosis of the distal end of the teat [4].

Thickness

Teat lacerations are classified as being partial thickness (skin to submucosa) or full thickness (skin to mucosa with milk leaking out of the incision) (Figs. 4 and 5). With full-thickness lesions, the defense mechanisms of the

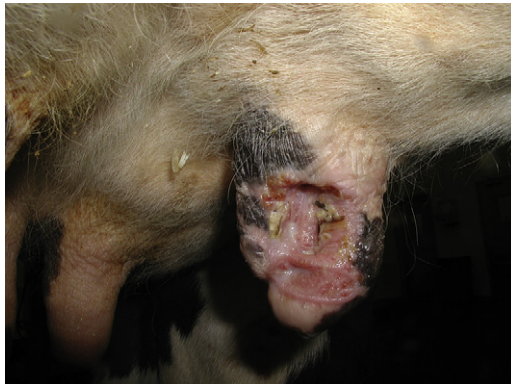

Fig. 1. Teat laceration healed by second intention ready to be revised and closed surgically to achieve first-intention healing. (Courtesy of P-Y Mulon, DVM, Montreal, Canada.)

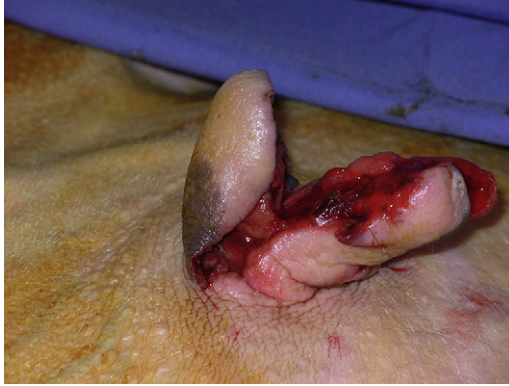

Fig. 2. Complex laceration. (Courtesy of P-Y Mulon, DVM, Montreal, Canada.)

teat against mastitis are bypassed, increasing the risk of clinical mastitis. Prompt surgical reconstruction of the injured tissue is needed to protect the quarter against environmental pathogens [5]. In cases of incomplete lacerations (when the integrity of the teat cistern has not been compromised), surgical intervention may not be necessary. In that situation, secondary healing by medical management of the wound may be sufficient. However, contraction of the tissue during healing can change the alignment of the teat creating problems during machine milking. With show cows, reconstructive surgery of the teat is necessary to obtain a satisfactory cosmetic outcome.

Preoperative therapy

All teat laceration surgeries are considered severely contaminated (Fig. 6). It is recommended to have the client apply cold hydrotherapy on

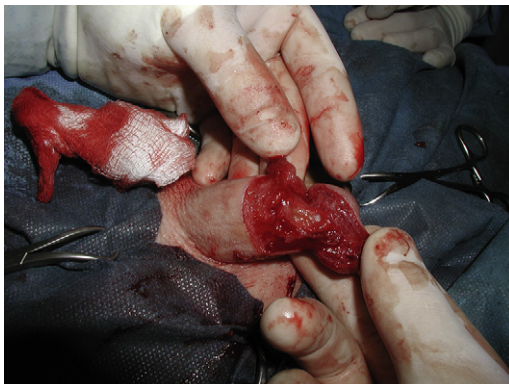

Fig. 3. Transverse laceration involving two thirds of the teat circumference. (Courtesy of P-Y Mulon, DVM, Montreal, Canada.)

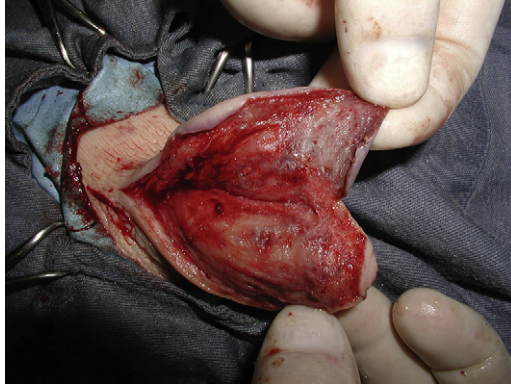

Fig. 4. Partial-thickness laceration. (The teat cistern has not been invaded.) (Courtesy of P-Y Mulon, DVM, Montreal, Canada.)

the injured teat while waiting for the veterinarian to get to the farm. The hydrotherapy helps decrease the inflammation and helps clean the teat for surgery. Before surgery, the cow is given a preoperative dose of antibiotic (procaine penicillin 22,000 IU/kg intramuscularly [IM] twice a day) and an NSAID (flunixin meglumine 1 mg/kg intravenously [IV]). The surgery can be performed in lateral or dorsal recumbency. The author prefers lateral recumbency because it decreases bloating on animals that have not been fasting. However, dorsal recumbency decreases the milk contamination improving the view of the surgical field. A clean area that will allow tying the animal's leg and that will provide sufficient lighting is selected. The author prefers giving a combination of drugs (neuroleptanalgesia) rather than using only an alpha-2 agonist that worsens bloating in ruminants. A combination of

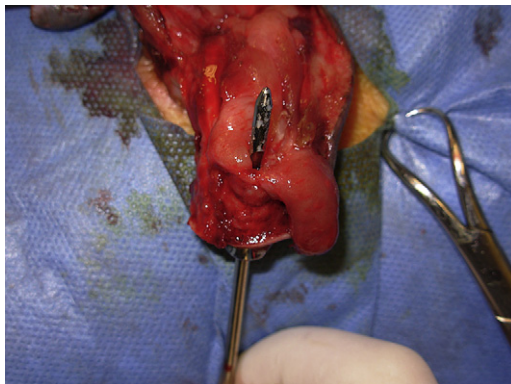

Fig. 5. Full-thickness laceration. (The teat probe has been entered through the streak canal.) (Courtesy of P-Y Mulon, DVM, Montreal, Canada.)

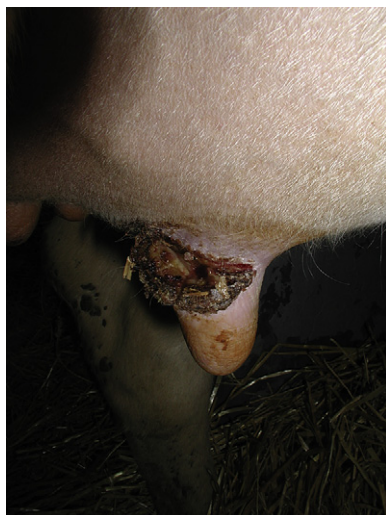

Fig. 6. Teat laceration severely contaminated.

xylazine (0.02 mg/kg), ketamine (0.04 mg/kg), and butorphanol (0.01 mg/kg) is given IV or IM (E.J. Abrahamsen, personal communication, 2005). Nervous animals can be given higher doses of ketamine (up to 2 mg/kg IM) during surgery. The animal is then cast down, and the legs and head are tied. The side on which the animal will lie is selected according to the location of the laceration.

The mammary gland is shaved, cleaned, and scrubbed. A local block is performed with 2% lidocaine HCL. A “V” block or a ring block is performed at the base of the teat. The teat cistern can be infused with lidocaine to anesthetize the mucosa.

Surgery

Surgical materials

A scalpel handle and a number 10 surgical blade are needed for debridement. A small-size Metzenbaum is appropriate to trim necrotic or redundant tissue. An Adson or Brown-Adson thumb forceps is needed for careful manipulation of the tissue. Using forceps with teeth at the tip causes less trauma than atraumatic forceps (DeBakey or Cooley), which crunch the tissue on a greater surface during manipulation [6]. If possible, the tissue should not be manipulated with forceps at all. A small-size needle holder and a regular size mayo scissor should be part of the teat surgery kit. A teat cannula, a syringe and some flushing solution should be available.

Absorbable suture material of size 3.0 to 4.0 mounted on an atraumatic needle should be available for suturing the mucosa and the subcutaneous

layers. Polyglycolic acid (Dexon II, Ethicon, Inc, Cincinnati, Ohio) or polyglactin 910 (Vicryl, Ethicon, Inc, Cincinnati, Ohio) are frequently used. When delayed healing is suspected or when clinical mastitis is present, a slow absorbable monofilament like polydioxanone (PDS II, Ethicon, Inc, Cincinnati, Ohio) may be more appropriate. Nonabsorbable monofilament of size 2.0 should be available to close the skin.

Wound debridement

The wound is carefully but aggressively debrided and lavaged. All the necrotic tissue is removed by scraping the tissue with a scalpel blade until viable tissue is exposed (pink and diffuse bleeding of the tissue) (Fig. 7). The margin of the skin may need to be trimmed using the scalpel blade or scissors.

Laceration repair

If involved, the mucosa and the submucosa are first reconstructed. A linear defect is reconstructed using a simple continuous pattern with a synthetic absorbable suture material (Dexon II, Vicryl) of size 3.0 or 4.0 mounted on a swedged-on atraumatic needle [7–9]. With complex configurations, a simple interrupted pattern may be used (Fig. 8). If delayed healing is suspected (extensive transverse laceration, mastitis), a slow resorbing monofilament suture (PDS II) is the preferred material to use [10].

The muscular and subcutaneous layers are closed with a simple continuous pattern with a synthetic absorbable suture material (Dexon II, Vicryl) of size 3.0 or 4.0 [7–9]. With large skin flaps, it is recommended to place some walking sutures (Fig. 9) to decrease dead space. However, doing so will increase the surgical time and the foreign material and may compromise the vascularization of the teat. Care must be taken to place only what is necessary to hold the flap safely.

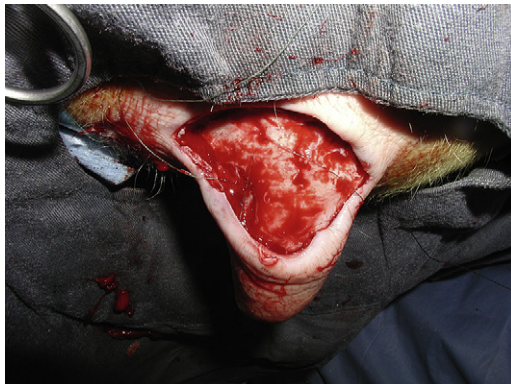

Fig. 7. Same teat as in Fig. 6 after aggressive debridement.

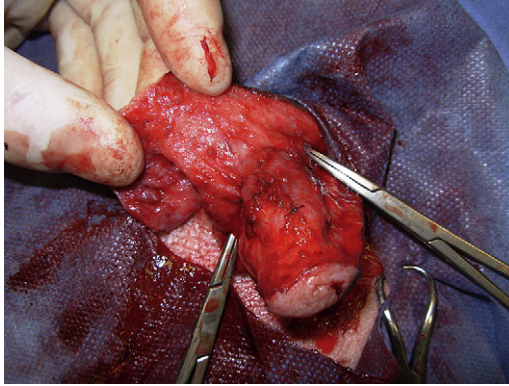


Fig. 8. Reconstruction of the damaged mucosa with a short, simple, continuous suture pattern. (Courtesy of P-Y Mulon, DVM, Montreal, Canada.)

The skin is carefully apposed with 2.0 synthetic nonabsorbable monofilament suture material (Prolen, Surgipro, Syneture TM, Norwalk, Connecticut) using a simple interrupted or cruciate pattern (Fig. 10) [7–9]. Care is taken to leave the skin sutures slightly loose because swelling is expected at the surgery site. When severe postoperative edema is suspected (transverse or chronic laceration), vertical or horizontal mattress sutures around or through stenting material (IV drop set) can be used to decrease risk of wound dehiscence (Fig. 11). With complex lacerations, a “V” flap will need to be sutured. However, dehiscence of the tip of the flap often occurs. A corner suture or a three-point buried mattress suture can be placed [6].

Throughout the procedure, the surgery site is lavaged frequently with saline. Antibiotics can be added to the lavage solution. The author routinely adds cefazolin (1 g/Liter) to the flush solution. Hemostasis is performed to avoid formation of mural hematoma that may obstruct the teat cistern during machine milking.

In the past, chronic catgut was used commonly in teat surgery. Because of the enzymatic reaction associated with its degradation, this material is not

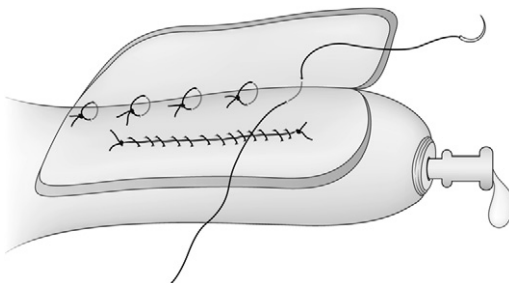


Fig. 9. Walking sutures allowing closure of a dead space.

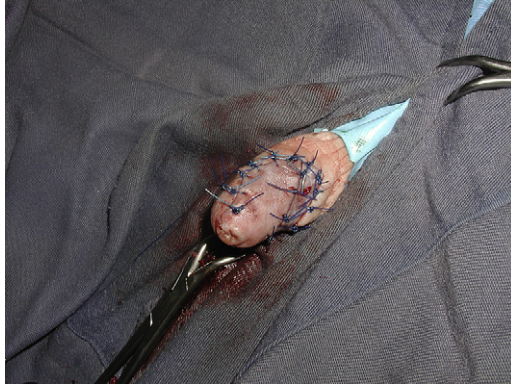


Fig. 10. Skin suture (simple interrupted stitches). (Courtesy of P-Y Mulon, DVM, Montreal, Canada.)

recommended in teat surgery. The synthetic materials listed above are more expensive, but they will increase your success rate for teat surgery.

Postoperative care

The wound is protected with a teat bandage, and the quarter is treated appropriately for mastitis. An NSAID (flunixin meglumine 1 mg/kg IV, once a day for 3 days) and antimicrobials (procaine penicillin 22,000 IU/kg IM twice a day for 3 days) should be continued postoperatively. Depending

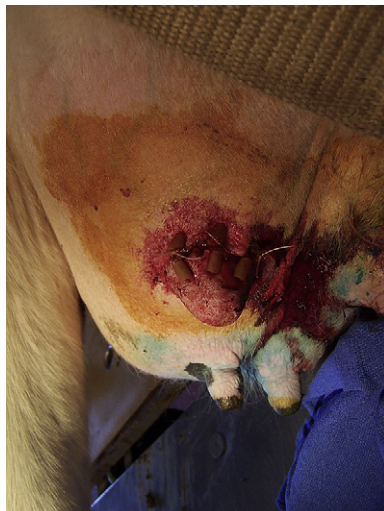

Fig. 11. Skin suture performed with horizontal mattress suture placed through plastic tubing to decrease tension on the suture and cutting effect on the skin.

on the severity of the lesion and the structures involved, milking with the machine may or may not be used at the following milking. A larger teat cup is recommended if a machine is used. Hand milking should be avoided because it is associated with wound dehiscence. If the machine is not used, a cannula is introduced carefully at every milking. When the streak canal is involved in the laceration, a cannula with a lid can be left in the streak canal for a few days (no more than 3 days) (Fig. 12). When the cannula is removed, a natural teat insert (wax implant) can be placed in the streak canal between milkings. It will promote the healing of the damaged streak canal.

Severe postoperative edema can be treated by applying ice around the teat for a few days. Crushed ice in a rectal sleeve can be placed around the teat. Commercial udder bags can be used to hold the ice in place. Twenty minute applications can be performed several times per day.

The skin sutures are removed no more than 9 days after the surgery. If the sutures are left in place longer, excessive fibrosis and suture tract infection may occur [3].

Complications and prognosis

Complications after surgical reconstruction of a teat laceration are wound dehiscence (Fig. 13), fistula formation (Fig. 14), mural abscess, teat cistern fibrosis, and mastitis [11,12]. If dehiscence occurs, the teat should be allowed to heal by second intention before attempting to repair. A fistula should be closed after complete healing of the laceration. The dimension of the fistula will decrease, and the surgery will be performed in healthy tissue. A mural abscess can be diagnosed with ultrasound scan. If small, it can be removed “en bloc” or it can be lanced and allowed to heal by second intention.

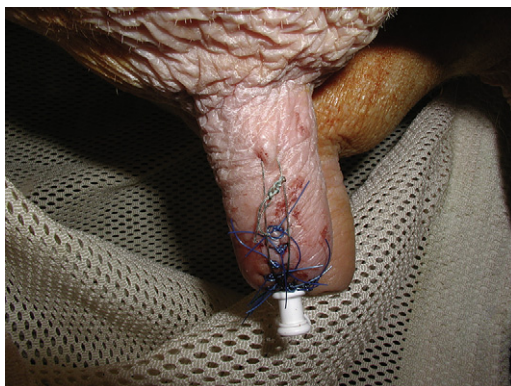


Fig. 12. A cannula with suture in place. The laceration was involving the distal aspect of the teat and the streak canal. (Courtesy of P-Y Mulon, DVM, Montreal, Canada.)

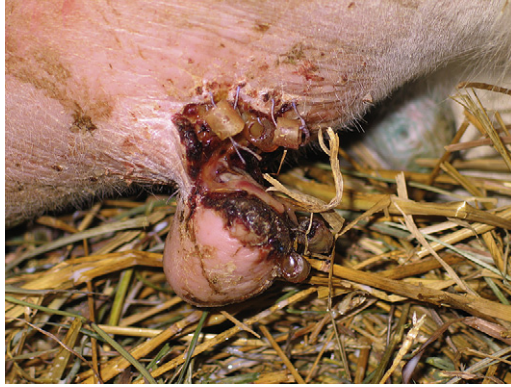

Fig. 13. Dehiscence of the repair a few days after surgery.

If the mucosa of the teat cistern cannot be closed, fibrosis of the cistern will occur. In this situation, a silicone implant can be placed in the cistern to avoid adhesion formation during the healing of the mucosa. However, the implant can create many problems. They can get dislodged or rupture, obstructing the normal milk flow. As a foreign material, they can also promote mastitis. When used, a second surgery often is needed to remove the implant.

Finally, especially when the distal end of the teat is involved (loss of the protective mechanisms against mastitis), clinical mastitis can become a real nightmare after teat laceration repair. With environmental mastitis, it is difficult to empty the quarter appropriately without damaging the repair. Frequent milking and antibiotic therapy should be started. If possible, bacterial culture and antibiotic sensitivity should be performed.

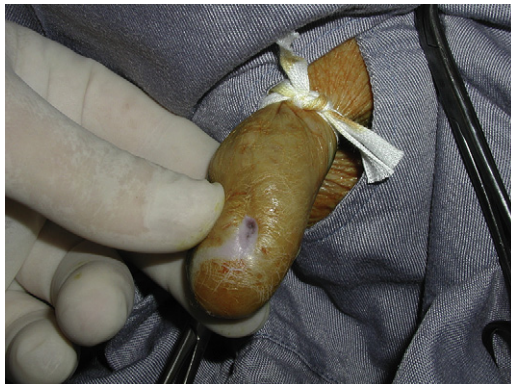


Fig. 14. Fistula formed after repair of a teat laceration.

Summary

Prompt surgery, aggressive debridement, careful reconstruction of the tissue, judicious use of suture materials, and appropriate postoperative therapy and monitoring are all key points to be successful in teat laceration surgery.

References

- [1] Beaudeau F, Ducrocq V, Fourichon C, et al. Effect of disease on length of productive life of French Holstein dairy cows assessed by survival analysis. *J Dairy Sci* 1995;78:103–17.
- [2] Michigan Dairy Herd Improvement Association. Annual summary. Lansing (MI): Michigan DHIA Inc.; 1981.
- [3] Couture Y, Mulon PY. Procedures and surgeries of the teat. *Vet Clin North Am Food Anim Pract* 2005;21:173–204.
- [4] Steiner A. Teat surgery. In: Fubini SL, Ducharme NG, editors. *Food animal surgery*. 1st edition. St. Louis (MO): WB Saunders; 2004. p. 414–8.
- [5] Dyce KM, Sack WO, Wensing CJG. The udder of ruminants. *Textbook of veterinary anatomy*. 2nd edition. St. Louis (MO): W.B. Saunders; 1996. p. 727–36.
- [6] Bailey JV. Principles of reconstructive surgery. In: Auer JA, Stick JA, editors. *Equine surgery*. 3rd edition. St-Louis (MO): Saunders; 2006. p. 254–68.
- [7] Ghamsari SM, Taguchi K, Abe N, et al. Effect of different suture patterns on wound healing of the teat in dairy cattle. *J Vet Med Sci* 1995;57:819–24.
- [8] Grymer J, Watson GL, Coy CH, et al. Healing of experimentally induced wounds of mammary papilla (teat) of the cow: comparison of closure with tissue adhesive versus non-sutured wounds. *Am J Vet Res* 1984;45:1979–83.
- [9] Makady FM, Whitmore HL, Nelson DR, et al. Effect of tissue adhesives and suture patterns on experimentally induced teat lacerations in lactating dairy cattle. *J Am Vet Med Assoc* 1991;198:1932–4.
- [10] Nichols S, Anderson DE. Time related breaking strength and elasticity of three synthetic absorbable suture materials incubated in phosphate buffered saline, milk and milk contaminated with *Streptococcus agalactiae*. *Am J Vet Res* 2007;68:441–5.
- [11] Ducharme NG, Arighi M, Horney D, et al. Invasive teat surgery in dairy cattle I. Long-term follow-up and complications. *Can Vet J* 1987;28:757–62.
- [12] Ducharme NG, Arighi M, Horney D, et al. Invasive teat surgery in dairy cattle II. Long-term follow-up and complications. *Can Vet J* 1987;28:763–7.