

Comparison of two surgical techniques for mastectomy of goats

Hussein M. El-Maghraby

Faculty of Veterinary Medicine, Benha University, El-Kalibia Province, Egypt

Accepted 10 December 2000

Abstract

Two different techniques for mastectomy were carried out on 14 goats with gangrenous mastitis. The animals were randomly assigned to one of two groups containing seven goats each. The first group was operated via a classical surgical mastectomy technique (either bilateral ($n = 5$) or unilateral ($n = 2$)). The second group was operated via vascular ligation of the external pudendal blood vessels and milk vein and amputation of the affected teat (either bilateral ($n = 3$) or unilateral ($n = 4$)). Comparison between the two groups was carried out. Vascular ligation and teat amputation proved to be an effective, quick, safe, and less expensive technique for mastectomy in goats. Ligation of udder vasculature was less traumatic than surgical amputation and the stress on the patient was minimal. © 2001 Elsevier Science B.V. All rights reserved.

Keywords: Goats; Gangrene; Udder; Mastectomy; Ligation

1. Introduction

The dairy goat has increased in popularity and in its ability to produce milk (Smith and Roguinsky, 1977; Abu-Samra et al., 1988). The increase in milk production by dairy goats has been associated with a similar increase in the prevalence and severity of diseases of the udder (Smith and Roguinsky, 1977). There are a variety of surgical conditions of the mammary gland of the goat that affect milk production (Hofmeyer, 1990). Gangrenous mastitis is one of the main diseases of dairy goats (Khamis and Saleh, 1972; Kerr and Wallace, 1978; Abdel-Maboud et al., 1984; Lewter and Walker, 1984; Abu-Samra et al., 1988). Caprine gangrenous mastitis is commonly caused by *Staphylococcus aureus* and less often by *Pasteurella haemolytica* (Linklater and Smith, 1993). In staphylococcal mastitis, toxemia and vascular

thrombosis occur. The resulting intoxication and ischemia cause gangrene of the affected gland (Kimberling, 1988).

The blood supply of the mammary gland of the goat is very similar to that of cattle (Habel, 1989; Dyce et al., 1996). Each half of the udder is supplied mainly by the external pudendal artery that emerges from the inguinal ring and gives a number of branches to the tissue of the udder and continues cranially as the superficial cranial epigastric artery (Hofmeyer, 1990). Each half of the udder is drained by a circular venous plexus derived mainly from the external pudendal vein, subcutaneous abdominal vein and the perineal vein (Kerr and Wallace, 1978). The relatively poor blood supply of the caprine udder together with the scarcity of anastomoses are considered to be predisposing factors for gangrenous mastitis in goats (Soliman et al., 1984).

Mastectomy is indicated for treatment of gangrenous mastitis and many other conditions, including chronic suppurative mastitis, pendulous udder,

E-mail address: humagh@yahoo.com (H.M. El-Maghraby).

chronic obstructive mastitis, and irreparable udder injuries (Oehme, 1988). Often, the affected udder is enlarged and highly vascularized making mastectomy (Youssef, 1999). Classical amputation of the bovine udder is a radical, high-risk procedure. A better alternative is the use of ligation of the external pudendal artery (Brewer, 1963; Horney, 1985). Amputation of the affected teat has also been described in association with vascular ligation for mastectomy in cattle (Noordsy, 1989). Ligation of bovine udder vasculature with subsequent sloughing of the affected quarters has generally supplanted surgical amputation (Noordsy, 1989). Nevertheless, ligation of the external pudic artery was not recommended as an alternative technique for surgical mastectomy in goats (Makady et al., 1990). The aim of this work is to study vascular ligation and teat amputation as an alternative technique for mastectomy in goats and to compare this technique with the routine, classical, total or partial mastectomy.

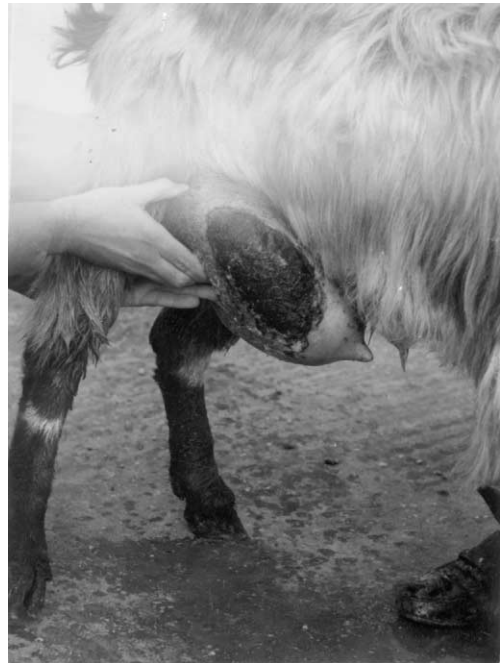

Fig. 1. Unilateral gangrenous mastitis in a goat.

2. Materials and methods

2.1. Animals

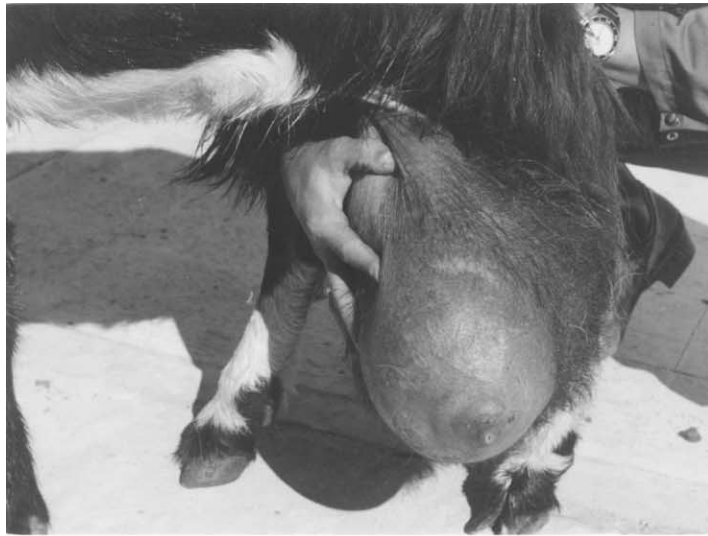Cadavers of five local breed goats were used in this study to determine the exact course of the different blood vessels, which supply the mammary gland in the goat. The most superficial and convenient sites of access to the superficial caudal epigastric vein (milk vein) and the external pudendal artery and vein were identified.

Fourteen adult female goats were presented to the clinic with gangrenous mastitis (Fig. 1). Diagnosis of gangrenous mastitis was accomplished by clinical signs discernible from careful examination of the udder. The gangrenous skin of the affected udder was discolored blue-black, insensible and cold with sharp line of demarcation from normal tissue. These animals were randomly assigned to one of two groups containing seven goats each. Goats were sedated by IM administration of Rompun (2% xylazine HCl solution) at a dose rate of 0.2 mg/kg body weight. Local infiltration analgesia using 1% lignocaine HCl solution was performed either in the form of field block at the base of the udder (group 1) or through

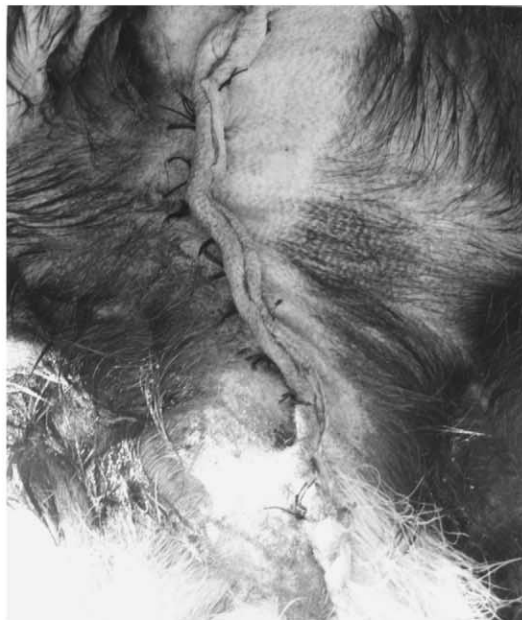linear infiltration analgesia at the level of the inguinal ring (group 2).

2.2. Surgical procedure

Goats in group 1 ($n = 7$) were operated via a classical surgical mastectomy technique (Fig. 2). Mastectomy was applied either unilaterally ($n = 2$) or bilaterally ($n = 5$). This technique was performed through an elliptical skin incision either around the base of the udder (bilateral mastectomy) or around the base of the selected half (unilateral mastectomy). Sufficient skin flap was left to cover the surgical area after udder removal. The area was bluntly dissected and the skin was reflected dorsally away from the glandular tissue and body wall. The glandular tissue was separated from the abdominal tunic. The main blood vessels (superficial caudal epigastric vein and external pudendal and perineal blood vessels) were located and double ligated by transfixing with No. 0 chromic catgut. The blood vessels and the suspensory ligament were severed. The glandular tissue was removed. The mammary lymph node was dissected



(a)



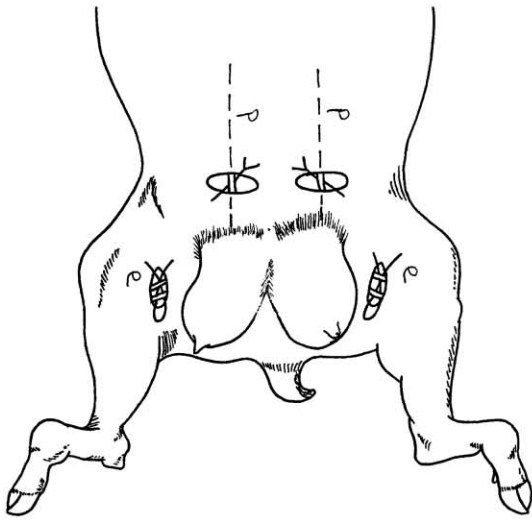
(b)

Fig. 2. Bilateral gangrenous mastitis in a goat: (a) swollen udder with marked exudative area; (b) closure after excision of the bilaterally enlarged udder with wide base attachment.

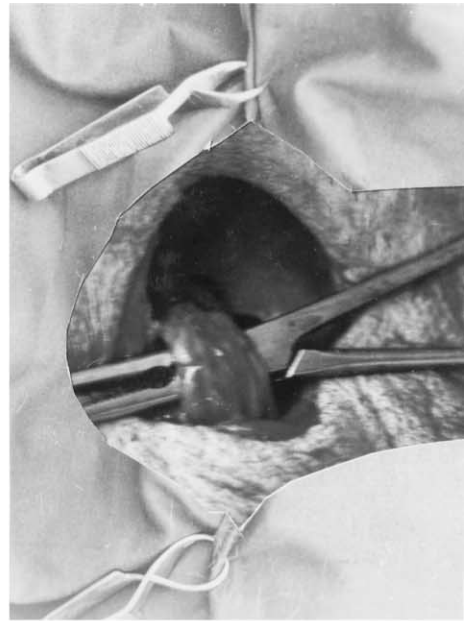with the gland. In cases of partial mastectomy, some connecting blood vessels between the udder halves were also ligated. The subcutaneous fascia was closed using No. 0 chromic catgut in a simple continuous

pattern. Skin was closed using silk (No. 1) in a simple interrupted pattern.

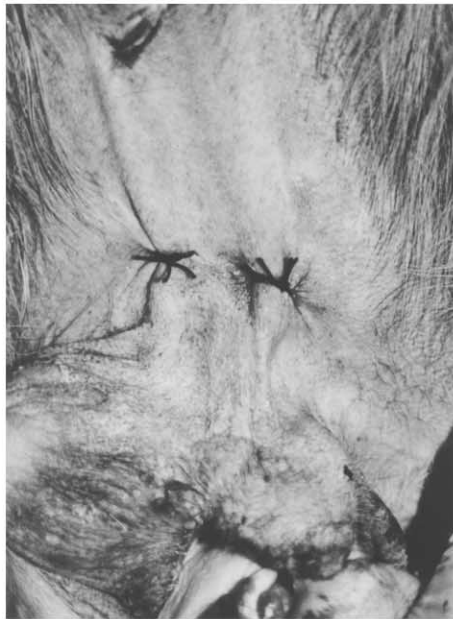Goats in group 2 ($n = 7$) were operated via vascular ligation and amputation of the teat (Figs. 3 and 4). This



(a)



(b)



(c)

Fig. 3. (a) Scheme showing ligation of udder vasculature in goats as a prelude to sloughing of the udder: Note the site of ligation for external pudendal artery and vein p and superficial caudal epigastric vein e; (b) isolation of the external pudendal artery and vein; (c) bilateral percutaneous ligation of the superficial caudal epigastric vein just in front of the mammary gland.

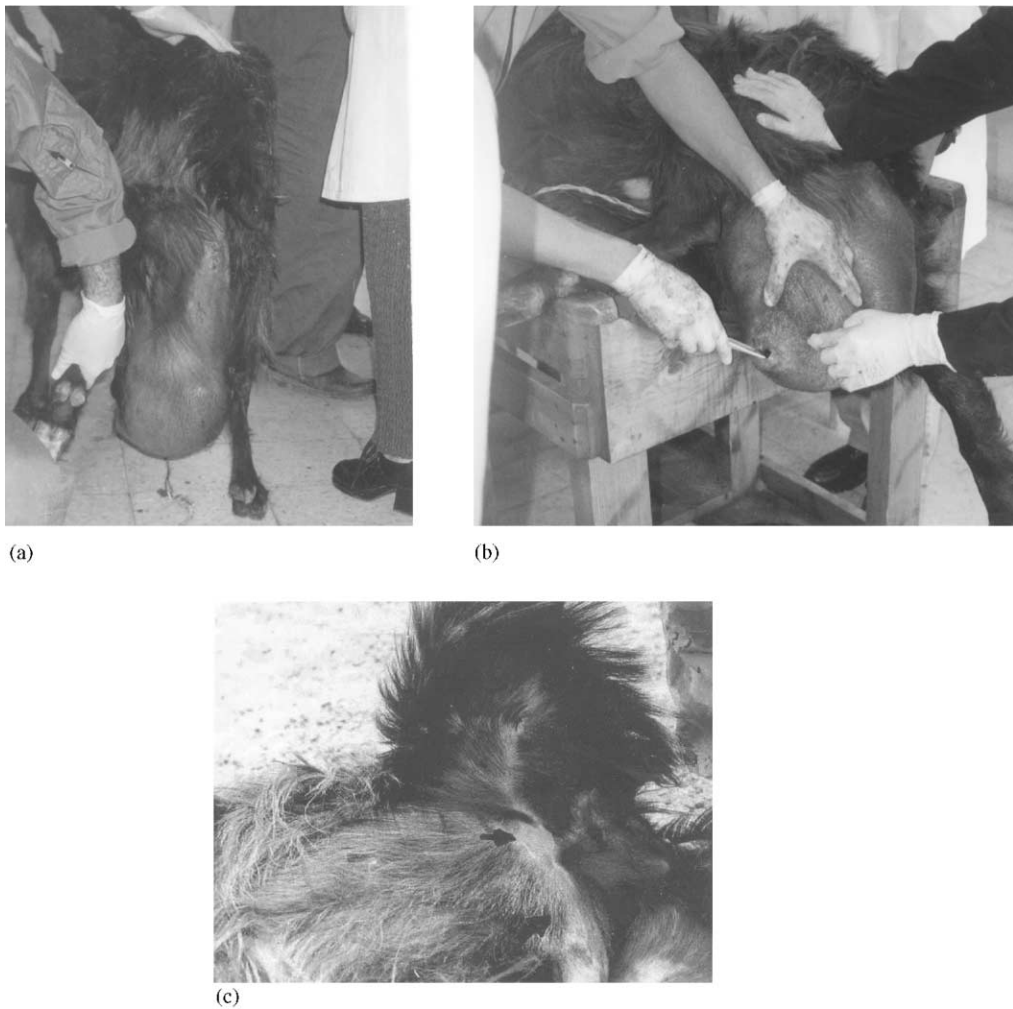

Fig. 4. (a) Bilateral gangrenous mastitis with wide diffuse abdominal attachment in a goat; (b) the same animal after amputation of the teat; (c) 3 weeks after teat amputation and vascular ligation, notice complete atrophy of the mammary gland, arrow.

technique was applied unilaterally in four goats and bilaterally in three goats. A linear oblique skin incision 5 cm length was performed at the level of the external inguinal ring (Fig. 3a). The landmark for this incision was 6–8 cm dorsolateral to the base of the mammary gland and at the level of its caudal–lateral border. Blunt dissection was performed and the external pudendal artery and vein were isolated, double ligated with No. 0 chromic catgut and severed in-between (Fig. 3b). Skin incision was closed using silk (No. 1) in a simple interrupted pattern. The superficial caudal epigastric vein (milk vein) was ligated perc-

tanously by using non-absorbable suture material (silk No. 2) just cranial to the dorsally positioned mammary gland (Fig. 3c). Amputation of the gangrenous teat following ligation of udder vasculature was performed by crushing of the teat with artery forceps followed by severance of the teat with a pair of scissors. The time from the beginning of the skin incision to the completion of the technique was recorded for each surgery. The animals were discharged from the hospital after surgery. Follow-up through physical examination was performed weekly for 1 month or until removal of the stitches

to clinically evaluate wound healing, sloughing of the mammary gland and/or any complications.

3. Results

Dissection of the mammary gland in goats revealed that the most convenient and superficial site for ligation of the pudendal artery and vein is about 6–8 cm dorsal to the base of the mammary gland and at the level of its caudal–lateral border. Meanwhile, the appropriate site for ligation of the superficial caudal epigastric vein is just in front of the mammary gland. The superficial caudal epigastric vein is almost 1.5 cm in diameter in this area and runs subcutaneously.

Gangrenous mastitis was recorded in 14 lactating goats. Eight goats had bilateral gangrenous mastitis, while the other six goats had unilateral gangrenous mastitis. The changes in the shape and size of the gangrenous udders were variable. Swollen, doughy and hyperemic udders with marked cold, exudative areas were noticed in ten cases while reduced, darkened, shrunken udders with easily detached thick scabs covering yellow caseated material were recorded in another four cases. In these four cases, fragments of the darkened and malodorous gland sloughed and temporarily hung from the animal by attached skin. In all of the cases, the gangrenous part of the udder was cold and insensitive, and surrounded by a thin red hyperemic zone. The distal portion of the udder, including the teat, was involved in most of the cases.

Bilateral radical mastectomy was technically easier to perform than unilateral mastectomy since several interconnecting blood vessels between the two halves of the udder need to be ligated during unilateral radical mastectomy. The average duration of surgeries were 25, 40, 14, and 22 min for partial and total amputation (group 1) and unilateral and bilateral ligation (group 2), respectively. Surgical ligation of the blood vasculature was associated with total atrophy of the gangrenous udder in all animals. Atrophy and subsequent complete sloughing of the ligated udder was recorded for 2–3 weeks postoperatively. No clinical differences were observed on the wound healing of both groups. No postoperative complications were recorded in this study.

4. Discussion

Vascular ligation and teat amputation proved to be an effective, quick and safe technique for mastectomy in goats. Ligation of udder vasculature was less traumatic and required less time, effort and expense than classical radical udder amputation. Vascular ligation is the technique of choice in case of gangrenous mastitis in goats with broad, diffuse attachment between the udder and body wall. Classical total mastectomy in goats with wide base udder and broad attachment is time consuming and more difficult than that with pedunculated udder and narrow attachment because of the need to create a skin flap (Youssef, 1999).

The technique of vascular ligation may also be preferred in the case of partial mastectomy to avoid hemorrhage of interconnecting blood vessels and severance of the suspensory apparatus. Since numerous interconnecting blood vessels are located between the two halves of the udder, the control of hemorrhage in partial surgical amputation needs more effort and time (De Lahunta and Habel, 1986, Youssef, 1999). Skin incision was closed after vascular ligation. However, suturing of the skin incision is questionable in light of the expected sloughing of the udder (Noordsy, 1989).

The goat's udder is suspended in the inguinal canal by suspensory ligaments. The medial and lateral ligaments hold each half of the udder (De Lahunta and Habel, 1986, Habel, 1989). The medial ligament, which is mainly elastic, originates in the *Linea alba* and is separated from the medial ligament of the other half of the udder by a small amount of connective tissue (Hofmeyer, 1990). In classical partial amputation, the halves of the udder should be separated between their medial suspensory ligaments. The cut-edges of the medial suspensory ligament should be sutured to support the ipsilateral half (Youssef, 1999). The lateral ligaments, which consist of dense collagen, protect the blood vessels of the udder and cover the lymph nodes above the caudal surface (Hofmeyer, 1990).

Ligation of bovine mammary blood vessels immediately retarded systemic absorption of toxins and greatly hastened the sloughing of the gangrenous tissue (Brewer, 1963; Noordsy, 1989). The amputation of a gangrenous teat is an important adjunct to vascular ligation. It provides drainage of mammary

exudates and toxins and allows air to enter the udder cistern, deterring potential growth of anaerobic bacteria (Noordsy, 1989).

Ligation of the milk vein (subcutaneous abdominal vein) was performed percutaneously by applying a surgeon's knot with marked tension. It has been shown that the subcutaneous abdominal veins could be ligated without any complications (Brewer, 1963). Identification and ligation of the external pudendal artery and veins in the goat was easy and quick. In this study, ligation of the perineal artery and vein was not performed due to their insignificant contribution. Similarly, their ligation in cattle is also optional (Noordsy, 1989).

The result of mammary vessels ligation in this study might differ from that of another report (Makady et al., 1990) which attributed the failure of atrophy in one goat with gangrenous mastitis (20%) and another two normal goats (40%) to the possibility of communication between the external pudendal artery and perineal artery in some goats. Failure of atrophy in normal goats might be due to the fact that a normal animal has less blood supply and less need for blood than one with gangrenous mastitis. However, the result of this study is consistent with others (Brewer, 1963; Noordsy, 1989). Due to the similarity of vascular supply, the same technique is applicable to sheep.

The most common complications following mastectomy in cattle are hemorrhage, shock, and infection (Oehme, 1988). None of these complications were recorded in this study. No marked difference was observed clinically in the wound healing of both groups. This is in agreement with Brewer (1963) who stated that after vascular ligation in cattle, the affected mammary gland sloughs out, and the wound heals more rapidly than it does when the circulation is intact.

In conclusion, though mastectomy has been recognized as a treatment for gangrenous mastitis in cattle and other ruminants, the present study demonstrates that ligation of the udder vasculature with amputation of the teat is the technique of choice for treating caprine gangrenous mastitis, especially in goats with a broad, diffuse attachment between the udder and body wall.

References

- Abdel-Maboud, M., Kamel, A., Mekky, N., El-Maghawry, S., 1984. The effect of gangrenous mastectomy on blood parameters in goats. *Vet. Med. J.* 32 (3), 29–33.
- Abu-Samra, M.T., Elsanousi, S.M., Abdalla, M.A., Gameel, A.A., Abdel Aziz, M., Abbas, B., Ibrahim, K.E., Idris, S.O., 1988. Studies on gangrenous mastitis in goats. *Cornell. Vet.* 78, 281–300.
- Brewer, R.L., 1963. Mammary vessel ligation for gangrenous mastitis. *J. Am. Vet. Med. Assoc.* 143, 44–45.
- De Lahunta A., Habel, R., 1986. *Applied Veterinary Anatomy*. 1st Edition, W.B. Saunders Co., Philadelphia, pp. 281–286.
- Dyce, K.M., Sack, W.O., Wensing, C.J., 1996. *Textbook of Veterinary Anatomy*. 2nd Edition, W.B. Saunder Co., Philadelphia.
- Habel, R.E., 1989. *Guide to the Dissection of Domestic Ruminants*. 4th Edition, Ithaca, NY, pp. 117–121.
- Hofmeyer, C.V., 1990. *Ruminant Urogenital Surgery*. 1st Edition, Iowa State University Press, pp. 148–170.
- Horney, E., 1985. Ligation of the external pudic artery. In: *Proceedings of the 13th Annual Veterinary Surgical Forum*, February 1985, San Diego, pp. 20–25.
- Kerr, J.H., Wallace, C.E., 1978. Mastectomy in goat. *VM/SAC* 9, 1177–1181.
- Khamis, M.Y., Saleh, M.S., 1972. Mastectomy as a radical treatment of mastitis in goat and sheep. *Vet. Med. J. (Giza)* 20, 273–278.
- Kimberling, C.V., 1988. *Jensen and Swift's Diseases of Sheep*. 3rd Edition, Lea & Febiger, Philadelphia, pp. 34–38.
- Lewter, M.M., Walker, R.D., 1984. Mastitis in goats. *Compend. Continuing Edu.* 6 (7), S417–S425.
- Linklater, K.A., Smith, M.C., 1993. *Diseases and Disorders of the Sheep and Goat*. Mosby-Wolfe Co., Torino, Italy, pp. 136–140.
- Makady, F.M., Saleh, A.S., Seleim, S.M., 1990. External pudic artery ligation in goats. *Assiut. Vet. Med. J.* 22 (44), 174–177.
- Noordsy, J.L., 1989. *Food Animal Surgery*. 2nd Edition, Vet. Med. Publishing Co., Kansas, USA, pp. 231–224.
- Oehme, F.W., 1988. *Textbook of Large Animal Surgery*. 2nd Edition, The Williams & Wilkins Co., Maryland, Baltimore, pp. 226–227.
- Smith, M.C., Roguinsky, M., 1977. Mastitis and other diseases of the goat's udder. *J. Am. Vet. Med. Assoc.* 171, 121–1248.
- Soliman, A.S., Ahmed, A.S., El-Keiey, M.T., Easa, M.S., Shokry, M.M., 1984. Complementary studies on gangrenous mastitis in goats. *J. Egyptian Vet. Med. Assoc.* 44, 67–76.
- Youssef, H.A., 1999. Mastectomy as a radical treatment for some prevalent udder affections in goats in Al-Gassem. *Assiut. Vet. Med. J.* 41 (82), 181–193.