

How to Skin-Graft in the Field

Richard P. Hackett, DVM, MS, Diplomate ACVS

Author's address: Department of Clinical Sciences, College of Veterinary Medicine, Cornell University, Ithaca, NY 14853; e-mail: rph2@cornell.edu. © 2011 AAEP.

1. Introduction

Skin grafting is often indicated for management of large, open limb wounds in horses.¹⁻³ Wound contraction is relatively ineffective in wounds below the carpus or tarsus due to lack of skin redundancy and mobility. If skin has been lost, healing will largely take place by epithelialization, a notoriously slow process that ultimately results in an unsightly and friable epithelial scar. Excessive reaction to wounding can result in exuberant granulation tissue as long as the wound remains unhealed by contraction or epithelialization. The primary reason for skin grafting in most cases is to accelerate healing and reduce the time the horse is under veterinary care and out of work. A secondary benefit may be improved cosmetic appearance and durability.

A variety of grafting techniques have been described in horses.¹⁻⁶ Skin grafts detached from one location and moved to another location, known as free grafts, are normally used. Free grafts can be either full-thickness skin or partial thickness. Grafts can be applied as small pieces of skin (island or seed grafts) or as sheets of skin. They may be placed on the surface of the wound or inserted into the granulation tissue bed. Each grafting technique has advantages and disadvantages, necessitating careful technique selec-

tion based on the wound, patient temperament, owner expectations, the practitioner's comfort level with a procedure, and available equipment and facilities.

The pinch grafting technique^{2,4,5} is particularly applicable for use in the field because it is technically simple to perform, can be done in the standing horse, and requires no special equipment. This procedure has an acceptable rate of success compared with other grafting techniques.^{2,4} This report will describe pinch grafting in detail.

2. Materials and Methods

Patient Selection

Pinch grafts are used in wounds on the distal limbs, particularly those with substantial tissue loss. Grafting is performed when the wound has reached a point at which it is no longer contracting, often a few weeks after the original injury. Previously exposed bone, ligaments, tendons, and other poorly perfused tissues should be covered with granulation tissue before pinch grafting. The recipient bed must be well vascularized and free of infection or exuberant tissue (Fig. 1). Chronic granulation tissue, exuberant or not, is highly fibrous and poorly vascularized (Fig. 2). The wound should be resected to a level of approximately 5 mm below the level of adjacent skin and

NOTES

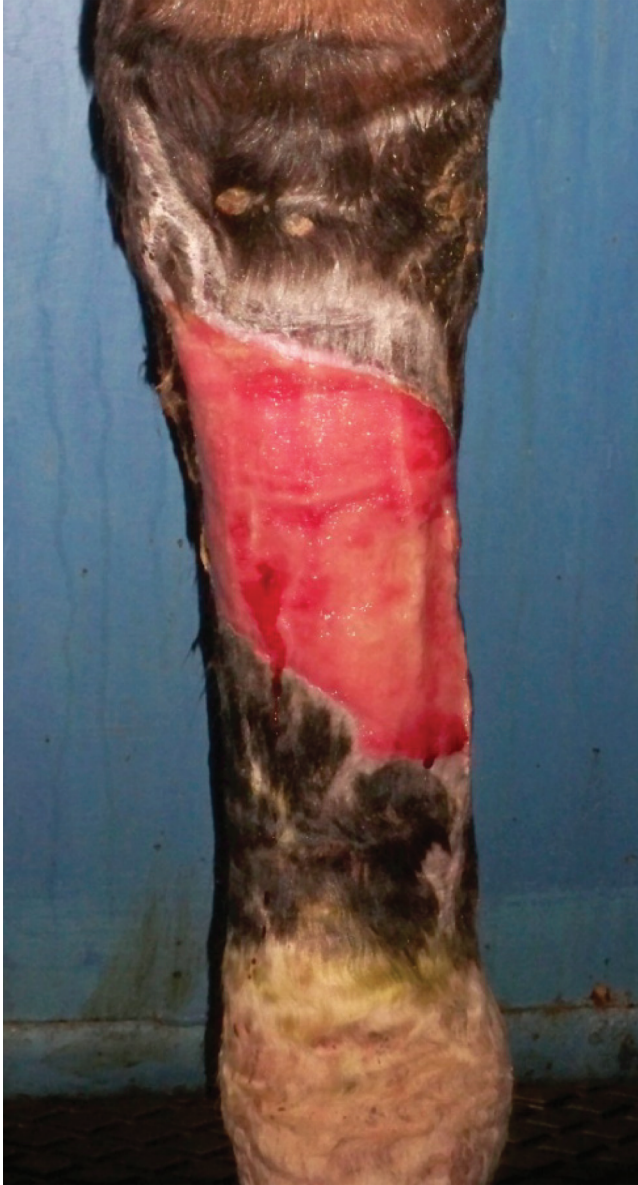

Fig. 1. Wound on the metatarsus that is an excellent candidate for pinch grafting as the bed is flat and highly vascular, with no evidence of infection.

pinch grafting performed 4 to 5 days later, when new highly vascular granulation tissue has filled the defect.

Graft Harvest

Horses are normally started on potassium penicillin^a (20,000 IU/kg IV qid), gentamicin^b (6.6 mg/kg IV q 24 h), and phenylbutazone^c (2 to 4 mg/kg IV or PO bid) before surgery and maintained for 5 to 7 days. Normally, pinch grafting is done with the horse standing and under appropriate sedation. The lateral cervical area under the mane is a convenient donor site and is used most commonly, but other cosmetically inconspicuous sites includ-

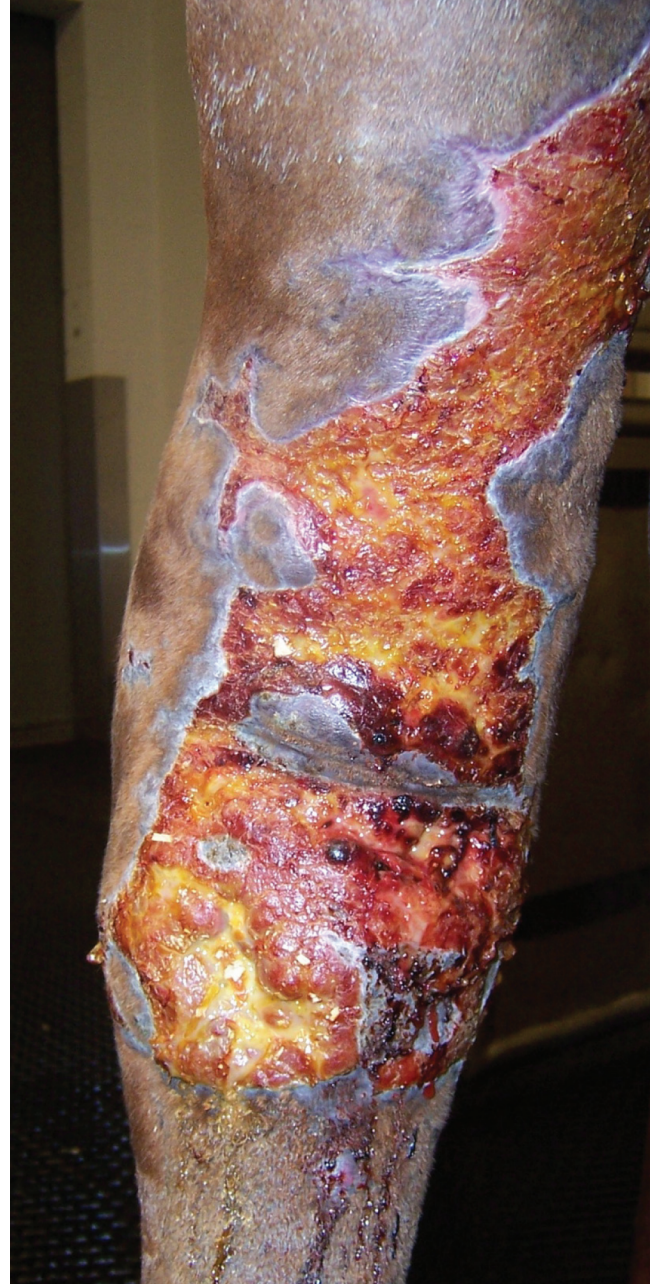

Fig. 2. Wound on the dorsum of the tarsus that is chronic and fibrotic and therefore a poor candidate for grafting unless granulation tissue is superficially excised and new tissue is allowed to fill the wound.

ing the pectoral area or perineum (hidden by the tail) may be used. The donor site is clipped, surgically prepped, and blocked by infiltration with local anesthetic. A small, curved suture needle held in a needle driver, a 20-g hypodermic needle, or a small forceps is used to tent the skin, and a No. 10 scalpel blade^d is used to excise a 4 to 5 mm diameter graft (Fig. 3). These grafts are thin on the periphery and thicker at the center (may be

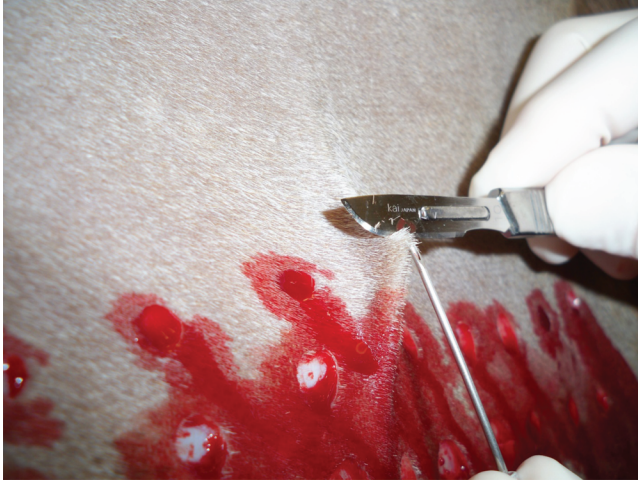

Fig. 3. Harvest of a pinch graft. The skin has been tented with a hypodermic needle and a scalpel blade is used to excise the graft.

full thickness in thin-skinned horses). Smaller-diameter grafts can be harvested but are more challenging to handle. Multiple grafts are harvested at once, leaving a 1 × 1-cm interval between harvest sites. Grafts are held in saline-moistened gauze sponges until implanted. Donor site wounds are usually partial thickness and do not require closure. Donor sites heal quickly, with little evidence of scarring (Figs. 4 and 5). If donor site wounds are full thickness, a single suture or staple can be placed if desired.

Graft Implantation

Local anesthesia of the wound bed is not necessary because granulation tissue is not innervated. Starting at the dependent part of the wound and

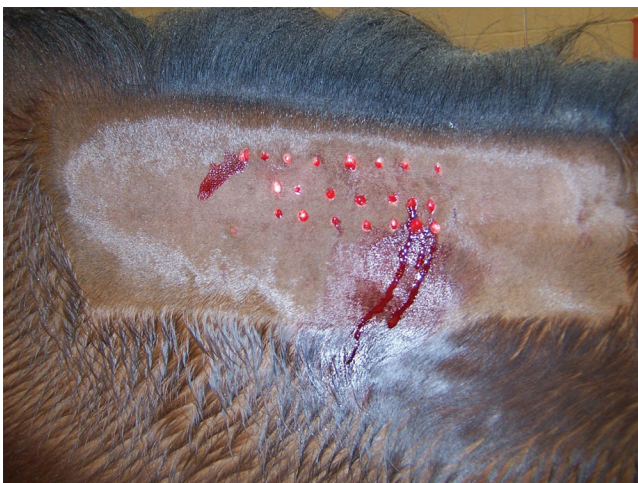

Fig. 4. Lateral cervical area used as donor site for pinch grafting immediately after surgery. No sutures were placed.

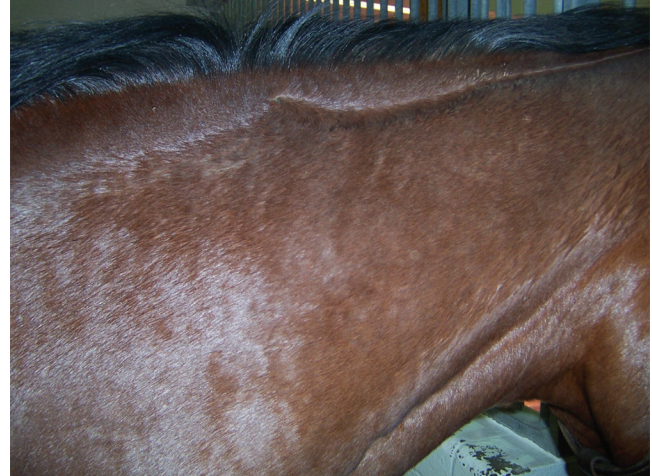

Fig. 5. Same site as Fig. 4, 4 months later. No scarring is visible, but small fibrotic areas are evident on palpation.

working dorsally, pinch grafts are placed on a 1 × 1-cm grid. A No. 15 scalpel blade^d is stabbed into the granulation bed in a ventral direction to make a 1-cm-deep pocket just below the surface of the granulation tissue. A pinch graft, with the epidermal surface most superficial, is inserted into the pocket, using splinter forceps^e (Fig. 6). Hair growth after pinch grafting is sparse and erratic, so it is not necessary to orient grafts by the direction of hair growth. An alternative technique is to use a curved mosquito hemostat to insert grafts in the granulation tissue without first making pockets.

Aftercare

The grafted area is covered with a sterile nonadherent pad,^f and the limb is placed in a pressure bandage. The bandage is changed at 2- to 4-day intervals, with care taken not to disrupt grafts at initial changes. Grafts initially appear as dark spots under the surface of the granulation tissue (Fig. 7). Granulation tissue overlying the graft will lyse or slough between 7 and 14 days, revealing pale, relatively inconspicuous grafts (Fig. 8). At 3 weeks, a ring of migrating epithelium should be prominent around each surviving graft (Fig. 9). These epithelial islands will rapidly coalesce with each other and with epithelial cells migrating from the wound margins (Fig. 10). Hair may begin to grow from the grafts by 42 to 56 days but will usually result in sparse tufts of erratic length and orientation. Instead of a pressure bandage, a cast should be used for the first 10 to 14 days after grafting of wounds over high-motion areas. Graft acceptance is usually 50% to 75%. It may take 2 to 3 weeks to be certain how many grafts have survived. At that time, if there are large areas in the granulation bed with no surviving grafts, re-grafting into those areas is indicated (Fig. 11). Graft failure is

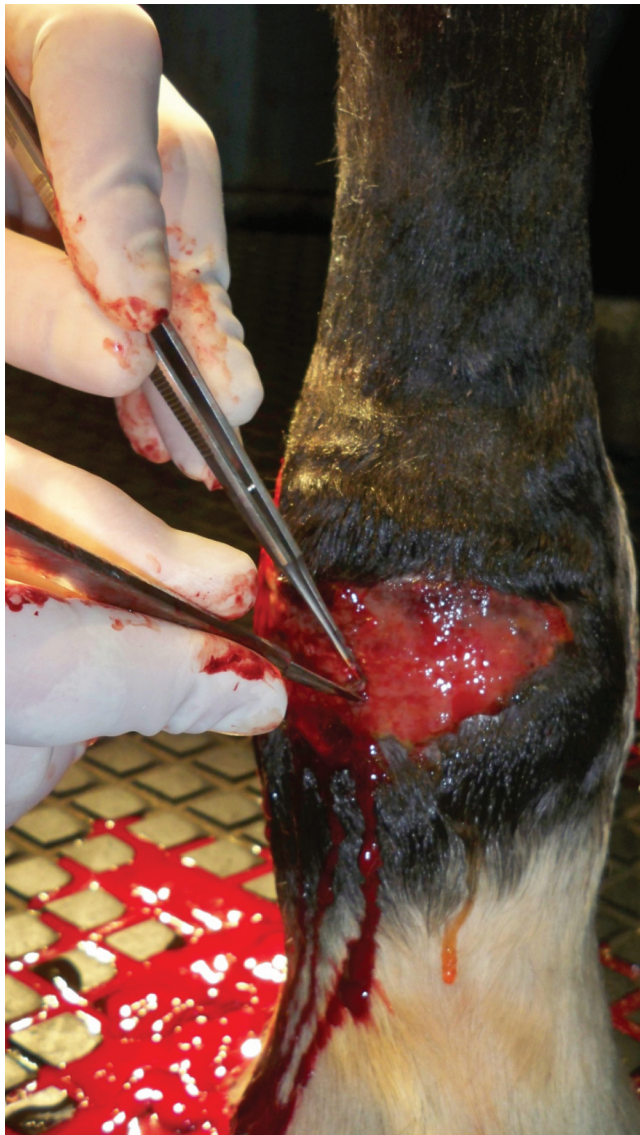

Fig. 6. Graft placement. A pocket with a dorsal opening has been made with the No. 15 blade, and splinter forceps are being used to insert the graft.

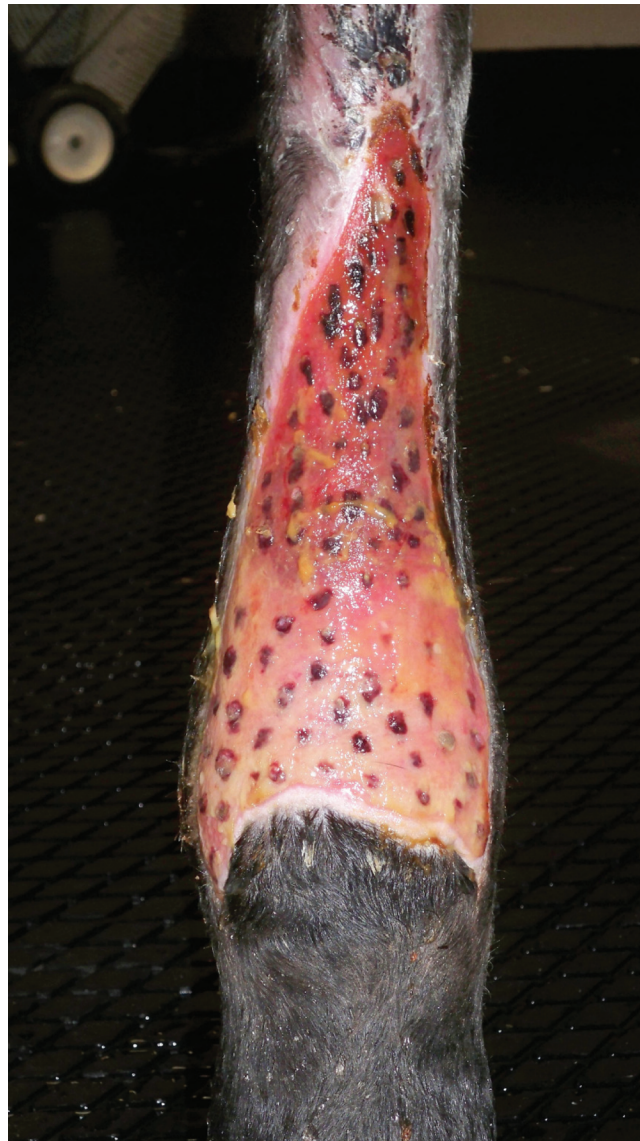


Fig. 7. A wound on the dorsum of the metatarsus 4 days after grafting. Grafts appear as dark spots in the granulation tissue. Note the 1 × 1-cm grid in which grafts were placed.

most commonly caused by infection, but a poorly prepared recipient bed or excessive motion at the grafting site may be factors as well.

3. Results

Pinch grafting is the most frequently used grafting technique in our hospital (4 cases in the last year). In almost all cases, healing is substantially accelerated with this technique, and owner satisfaction is good.

4. Discussion

Pinch grafts are the easiest way to perform skin grafting in horses and is a technique requiring no specialized equipment. It is highly applicable to

the field practitioner but is also commonly used in referral hospitals. The prime objective of skin grafting is usually to accelerate wound healing and get the horse back to work. Pinch grafts achieve these goals very well. Each surviving pinch graft is an epithelial island, sending new epithelial cells in all directions to merge with cells from other grafts and with epithelial cells from the skin margins, dramatically reducing time necessary for wound epithelialization. The cosmetic outcome, however, is not substantially different from what would have been achieved had epithelialization from the skin margins been allowed to proceed naturally. The ultimate appearance is a weak epithelialized scar with little or no hair covering.

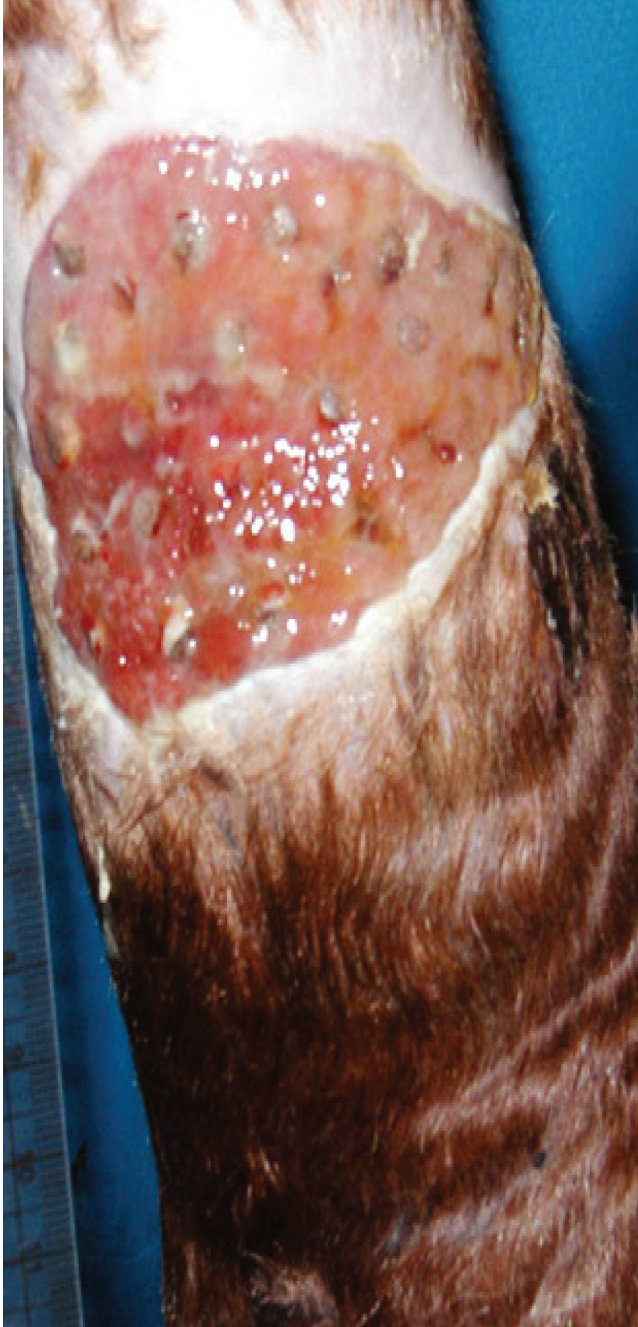

Fig. 8. Metatarsal wound approximately 10 days after pinch grafting. Overlying granulation tissue has lysed and pale grafts are evident.

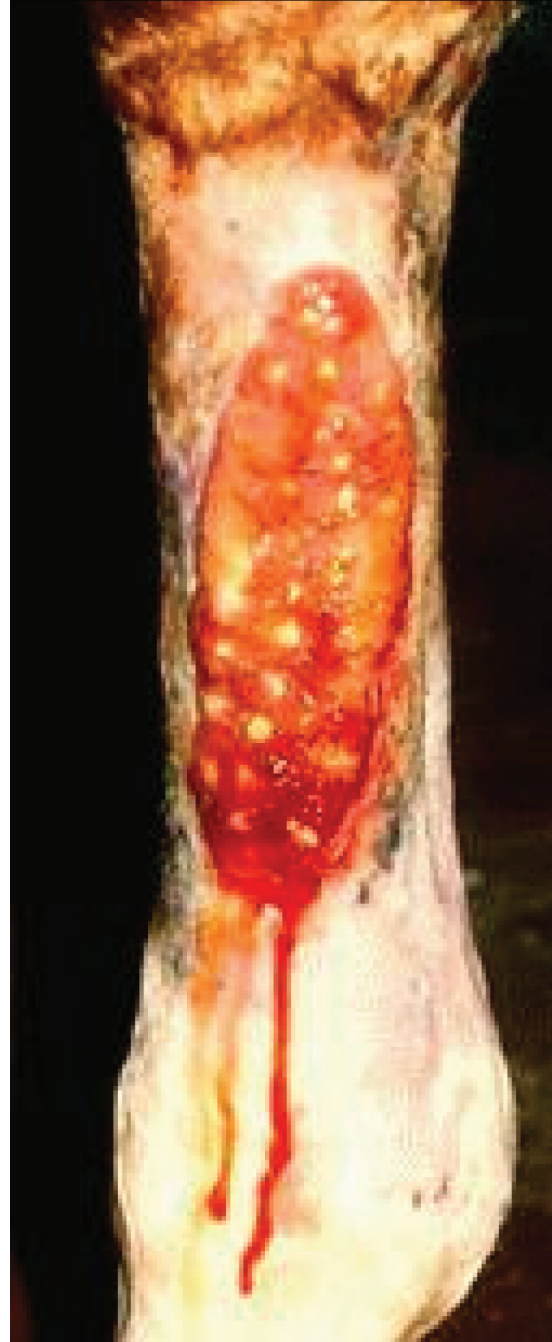

Fig. 9. Epithelial islands are evident in this metatarsal wound (approximately 3 weeks after grafting).

These grafts are small and predominantly split thickness, so few hair follicles are transplanted; even fewer survive the severe hypoxia immediately after grafting. Despite these disadvantages, pinch grafting has clear value in wound management.

Other options for skin grafting, some with improved cosmesis, can be considered in the field. In punch grafting, full-thickness plugs of skin are

harvested, using skin biopsy punches that are then placed into holes in the granulation tissue made with slightly smaller skin biopsy punches.⁴ Tunnel grafts are narrow strips of skin that are passed through tunnels in exuberant granulation tissue, a technique particularly useful for wounds on the dorsum of the hock.¹ These grafting techniques are more technically challenging than pinch grafts and require some special equipment.

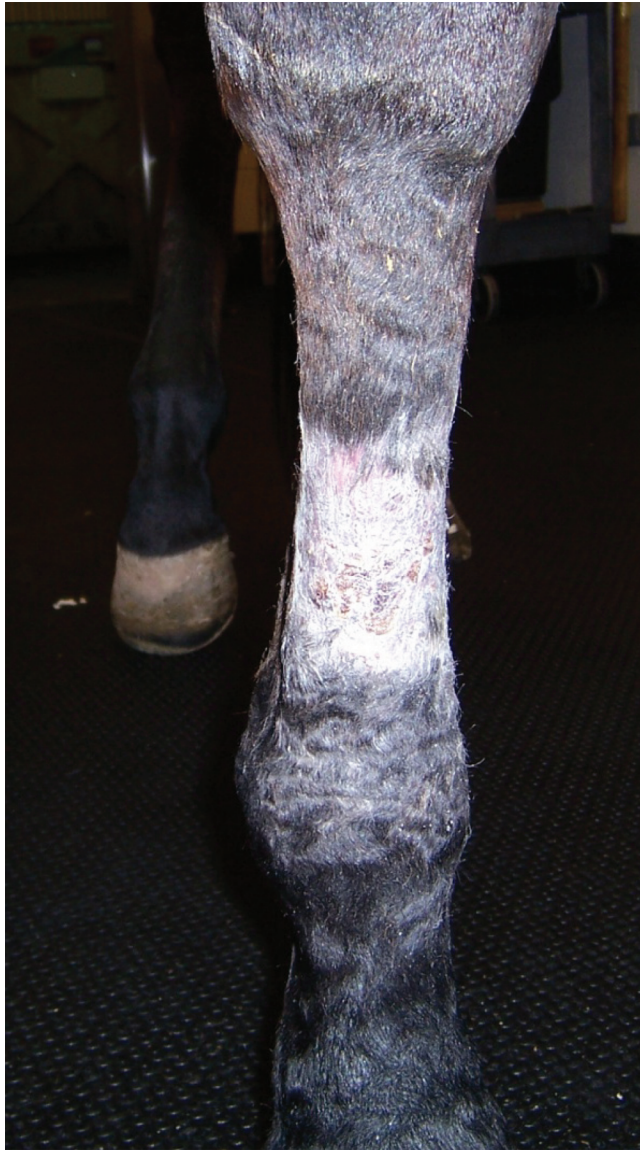

Fig. 10. Metacarpal wound 6 weeks after pinch grafting.

If successful, they are effective in promoting epithelialization and, as full-thickness grafts, have at least the potential to provide better hair coverage. Unfortunately, the ultimate cosmetic outcome is often not markedly different from that achieved with pinch grafting.¹ Full-thickness skin grafts have recently been described for clinical use in horses.⁶ Skin can be harvested from the pectoral area in a standing horse and, after meticulous removal of the subcutaneous tissues, applied to the wound. If successful, this technique leads to excellent cosmetic results and durability, but coverage of larger wounds is limited by availability of donor skin.

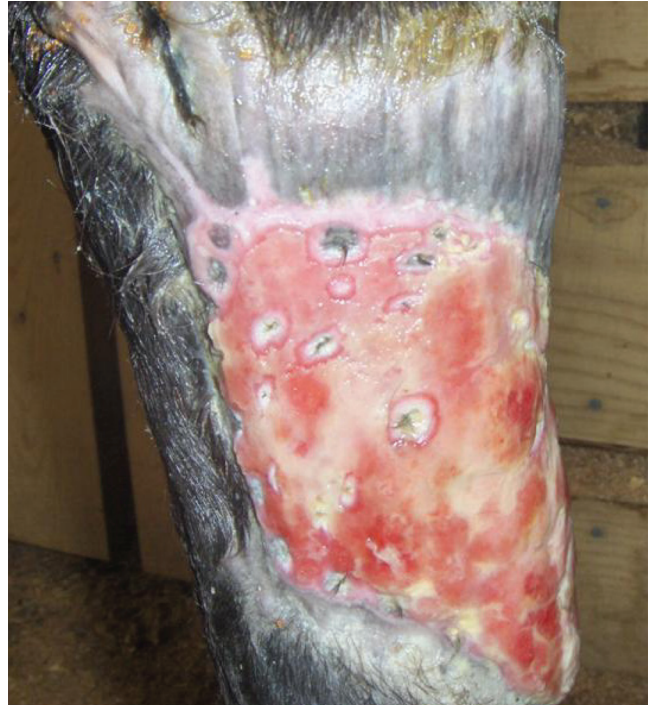

Fig. 11. Proximal metatarsal wound 8 weeks after grafting. A few epithelial islands are evident, but little overall epithelialization has occurred. The pale and fibrotic granulation tissue should be excised and allowed to fill with fresh tissue before a second grafting attempt.

References and Footnotes

1. Schumacher J, Wilmlink JM. Free skin grafting. In: Stashak TS, Theoret C. *Equine Wound Management*. 2nd ed. Ames, IA: Wiley-Blackwell, 2008;509–542.
2. Bristol DG. Skin grafts and skin flaps in the horse. *Vet Clin North Am Equine Pract* 2005;21:125–144.
3. Rakestraw PC, Taylor TS, Schumacher J. How to harvest, store, apply, and manage split thickness meshed grafts in horses. In *Proceedings*. Am Assoc Equine Pract 2001;47:433–436.
4. Dahlgren L, Booth L, Rienertson EL. How to perform pinch/punch grafts for the treatment of granulating wounds in the horse. In *Proceedings*. Am Assoc Equine Pract 2006;82:626–630.
5. Mackay-Smith MP, Marks D. A skin grafting technique for horses. *J Am Vet Med Assoc* 1968;152–163.
6. Tóth F, Schumacher J, Castro F, et al. Full-thickness skin grafting to cover equine wounds caused by laceration or tumor resection. *Vet Surg* 2010;39:708–714.

^aPfizerPen, Pfizer, Inc., New York, NY 10017.

^bGentamicin sulfate solution, Sparhawk Laboratories, Lenexa, KS 66215.

^cButaject, Butler Schein Animal Health, Dublin, OH 43017.

^dMiltex Carbon steel surgical blades, Miltex, Inc., York, PA 17402.

^ePlain Splinter Forceps, 4.5 inches, Miltex, Inc., York, PA 17402.

^fSterile non-adherent pad. Dukal Corp., Hauppauge, NY 11788.